

Case Report

Interdisciplinary Management of an Endo-Perio Lesion in a Chronic Hepatitis Patient-A Case Report

Khyati Chandra, Gayathri GV*, Sartaz Rahman, Mehta DS

Department of Periodontics, Bapuji Dental College and Hospital, Karnataka, India

*Corresponding Author

Gayathri GV, Department of Periodontics, Bapuji Dental College and Hospital, Davangere, 577004, Karnataka, India; E-mail: gayathri_dental@rediffmail.com

Received: 04 August 2019;

Accepted: 06 September 2019;

Published: 16 September 2019

Citation: Chandra K, Gayathri GV, Rahman S, Mehta DS. Interdisciplinary Management of an Endo-Perio Lesion in a Chronic Hepatitis Patient-A Case Report. Dental Research and Oral Health 2 (2019): 032-039.

Abstract

Management of Endo-perio lesions have always been a dilemma to the dental clinician. Apicectomy is usually the treatment of choice, when conventional endodontic treatment fails. In the present case scenario, a 42 year old male patient reported with pain and pus exudate in upper left anterior teeth since three months. Patient gave a history of Root Canal Treatment (RCT) in relation to 23 and 24 five months back. The medical history of the patient revealed that, a year ago he had undergone treatment for hepatitis. A physician was consulted prior to initiation of dental treatment and an interdisciplinary approach was planned for the management of the patient. Apicectomy was performed under strict aseptic condition and the osseous defect was treated with Novabone putty, collagen membrane and Platelet Rich Fibrin (PRF). One year follow up revealed, defect fill, gain in clinical attachment, improved gingival biotype and increased width of attached gingiva. Hence, it can be concluded that the synergistic effect of suitable medical care, use of various regenerative materials along with periapical root sealing brings about clinical and radiographic improvement in endo-perio lesions of chronic hepatitis patients.

Keywords: Endo-perio; Apicectomy; Chronic hepatitis; Tissue regeneration

Clinical Relevance to Interdisciplinary Dentistry

- The Case report depicts an endo-perio lesion in a chronic hepatitis patient which has been managed using a multidisciplinary approach.
- Apicectomy was carried out by an endodontist followed by regenerative therapy performed by the placement of bone graft and PRF membrane by a periodontist keeping in mind the safety protocols as suggested by a physician.
- This collaborative effort has yielded excellent results in tissue regeneration despite the presence of systemic impediments.

Introduction

The endodontic and periodontal tissues share an embryological, biological and functional concordance. The relationship between periodontal and pulpal disease was first described by Simring and Goldberg in 1964 [1]. Both the tissues are ectomesenchymal in origin and this embryologic association serves as a conduit for anatomical intercommunications between the pulp and periodontium. Hence, inflammatory components in the pulp may lead to widespread destruction of the periodontium and periodontal breakdown may cause pulpitis [1]. These lesions have always presented themselves as perplex situations for the dental clinician. When periodontal pockets are associated with an endodontically compromised teeth, the clinical situation complicates the outcome of the conventional endodontic therapy. Periodontal surgical intervention is indicated, when the ultimate goal of therapy is to eliminate the periapical lesion and allow soft and hard tissue regeneration [3].

According to various studies, paraendodontic surgeries give a success rate of 91.6%, while failure rate is shown to be 4.7% [4]. However, its prognosis can be influenced by several factors such as the presence of systemic conditions such as diabetes, hypertension, chronic bacterial and viral infections like HIV, Chronic hepatitis etc. Among various infectious ailments, chronic viral hepatitis is distinct, as the virus harbours in hepatocytes, leading to necroinflammatory liver disease. This causes altered immunoinflammatory status and impaired wound healing. Quite often, hepatitis results in depressed plasma levels of coagulation factors that need a careful evaluation of hemostasis prior to treatment [5].

The present case report depicts a clinical scenario, in which apicectomy and regenerative periodontal surgery was performed in a patient with chronic hepatitis following conventional endodontic treatment failure. One year postoperative re-evaluation showed affirmative tissue regeneration.

Background

A 42 year-old male patient reported to the Department of Periodontology, Bapuji Dental College and Hospital with a chief complaint of pain and pus discharge through gums of the left upper anterior teeth. Patient gave a history of trauma to the upper anterior teeth 1 year back. He had visited a private dental clinic 5 months back for pain and swelling and had undergone root canal treatment for the same. Medical history revealed that he had undergone treatment for hepatitis B one year back and was currently not on any medication.

Intra oral examination revealed that the patient's oral hygiene maintenance was good (OHIS score-0.4). Gingiva in relation to 23 and 24 was erythematous and edematous. There was purulent discharge from the

sulcular area, grade 1 mobility, probing depth of 8- 10 mm and vertical tenderness on percussion was present with respect to 23 and 24. Gingival recession of 2 mm was present in relation to 23 and gingival margin was there at the level of Cementoenamel junction (CEJ) in relation to 24. IOPA revealed interdental bone loss till apical one third & existence of residual periapical radiolucency in relation to the RCT treated teeth. The case was diagnosed as primary endodontic lesion with secondary periodontic involvement. Hence it was decided to manage the case with an interdisciplinary approach in association with a physician, an endodontist and a periodontist. Treatment protocol was explained and a written consent was obtained from the patient. Due to his medical history, routine blood investigations were advised and presence of HBsAg was detected. The patient was confirmed to be in an inactive carrier state of Hepatitis after evaluating results of Serum HBV DNA (Hepatitis B Virus Deoxy ribonucleic acid) test, ALT/AST (Alanine transaminase/ Aspartate transaminase) levels and Liver biopsy test. Other investigations including Complete Blood Count, Partial Thromboplastin Time (PTT), International Normalized Ratios, bleeding time, liver function tests, platelet count etc were found to be within normal range. Following physician's consent, non surgical periodontal treatment was initiated and surgical treatment was scheduled after 3 weeks.

Procedure

After administration of local anesthesia (2 % Lidocaine 1: 80,000 adrenaline), a full thickness mucoperiosteal flap was raised by extending vertical incisions from mesial aspect of 23 to mesial aspect of 25 using #15 Bard Parker (B.P) blade and periosteal elevator. Apical curettage was performed. 3.0 mm of the root apex was surgically resected in relation to 23 and 24 using a

surgical bur. Ultrasonic tips were used to make a 3.0-mm deep retro preparation. After hemostasis was achieved, retropreparation was disinfected and dried. The retrograde filling was done with Mineral Trioxide Aggregate (MTA fillapex, Dentsply, Germany). Bone Putty (Novabone, UK) was then placed to fill the bony defects. This was succeeded by the placement of collagen and A-PRF membrane on the surgical site. The flap was then repositioned and secured with interrupted sutures by using 4-0 black braided silk (Figure 1).

Amoxicillin 500 mg t.i.d for 5 days, Ibuprofen 400mg t.i.d for 3 days and 0.2% chlorhexidine mouthwash was prescribed postoperatively. Suture removal was done 10 days after the procedure. Patient was comfortable and the operated site revealed uneventful tissue healing on 10th day.

One year post-operative IOPAR, showed increased radiopacity in perapical and interdental area (Figure 1, 7a & 7b). There was also an improvement in the gingival biotype, clinical attachment level and width of attached gingiva (Figure 2, Table 2).

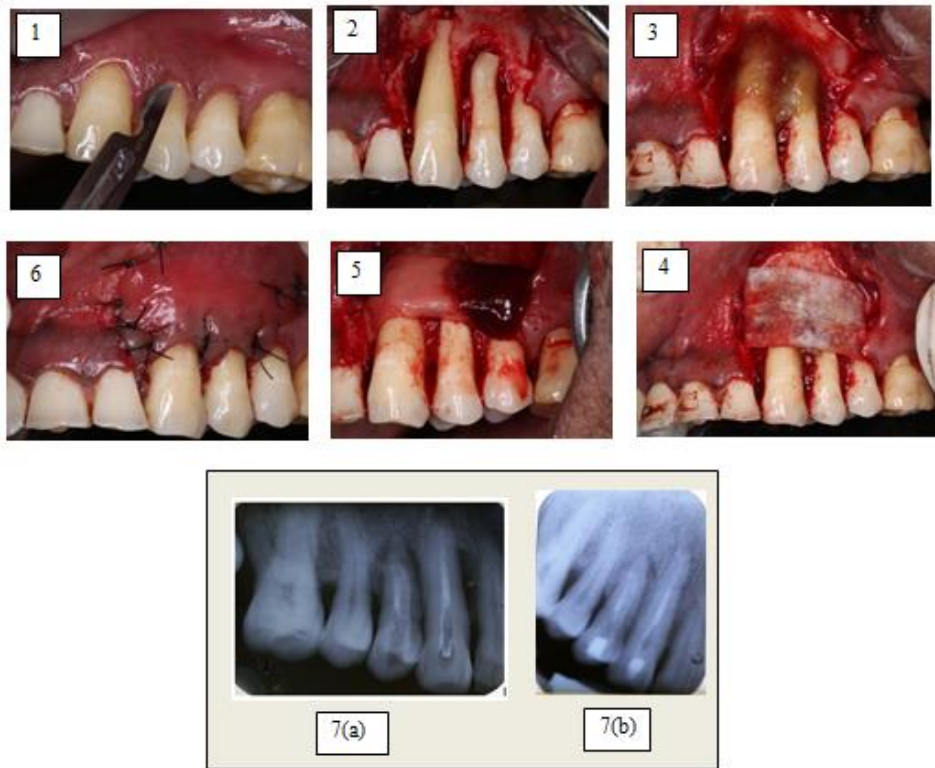


Figure 1: (1) Incision given; (2) Apicetomy cut given; (3) Nova bone putty placed; (4) Collagen membrane placed; (5) PRF membrane placed; (6) Sutures placed; (7a) Immediate post-op intra-oral periapical radiograph; (7b) Intra-oral periapical radiograph after 1 year.

<p><u>Local Anaesthetics :</u></p> <p>Lidocaine Mepivacaine Prilocaine Bupivacaine</p>
<p><u>Analgesics:</u></p> <p>Aspirin Codein Ibuprofen</p>

Acetaminophen
<p><u>Sedatives</u> Diazepam** Barbiturates**</p>
<p><u>Antibiotics</u> Ampicillin Tetracycline Metronidazole*** Vancomycin***</p>
<p>Legend</p> <p>*limit dose if severe liver disease or haemostatic abnormalities present</p> <p>**limit dose if severe liver disease or encephalopathy is present</p> <p>*** avoid if liver disease is present</p>

Table 1: Drugs used in liver disease.

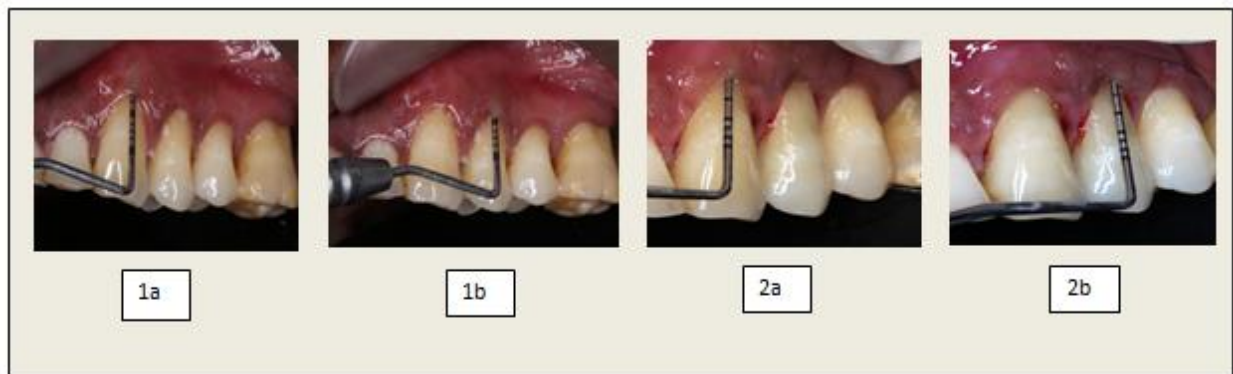

Figure 2: (1a, 1b) Pre-operative probing depth; (2a, 2b) Post-operative probing depth.

		Tooth number	
		23	24
Probing Depth (PD)	Pre-op Post-op	8mm 3mm	10mm 3mm
Clinical Attachment Loss (CAL)	Pre-op Post-op	10mm 5mm	10mm 3mm
Gingival Biotype	Pre-op Post-op	0.5mm 1mm	0.5mm 1.5mm
Width of the Attached gingiva	Pre-op Post-op	1mm 3mm	0mm 1mm

Table 2: Clinical parameters for assessing improvements in the affected teeth

Discussion

There are many implications for a patient suffering from a liver disorder, when they have to undergo a dental treatment procedure. Thorough medical and dental histories are essential before proceeding with treatment of any sort. It is prudent to discuss the details of the disease with a treating physician, in order to provide the patient with a dental treatment plan that is safe and appropriate for them [5]. The given patient was confirmed to be in an inactive HBsAg carrier state as determined by the following:

1. HbsAg positive > 6 months
2. HBeAg negative, anti-HBe positive
3. Serum HBV DNA $<10^5$ copies/mL
4. Persistently normal ALT/AST levels
5. Liver biopsy confirms absence of significant hepatitis (necroinflammatory score <4). Although the patient was in an inactive carrier state, the risk of transmission cannot be eliminated. Thus the operating clinicians were vaccinated and CDC guidelines were strictly followed and customized drugs (Table 1) were used [5]. Apicectomy can be indicated in several

clinical situations, namely persistence of periapical lesion following conventional RCT, perforations, fractured instruments and presence of external resorption. In this case, the apical portion of the root was cut 45° angle to the long axis of the tooth. This inclination degree was appropriate to allow total root surface exposure thus facilitating operative procedures [6].

Novabone has a property of releasing Ca, P and Si ions which stimulates osteoblasts. As ion release progresses, nova bone is transformed into an increasingly porous scaffold with increased surface area, that boosts the natural healing process [7].

Guided tissue regeneration (GTR) membranes have been known to encourage regeneration by preventing epithelial cell migration and facilitate faster wound maturation. They also act as lattice for migrating periodontal ligament fibroblasts thus making them exemplary regenerative materials [8].

PRF, a second generation platelet concentrate releases platelet cytokines and growth factors which particularly favours cell migration and serves as a matrix to accelerate wound healing [9]. Therefore the placement of collagen membrane followed by the use of PRF has been propagated. As the PRF membrane degenerates within 7 to 11 days with release of incorporated growth factors. Since guided periodontal regeneration warrants at least a period of 4 to 6 weeks of epithelial cell exclusion hence use of PRF alone as a barrier membrane may be insufficient [10]. Thus the combination of both the collagen and PRF membrane

form an ideal barrier membrane in regenerative therapy.

Conclusion

This case report depicts an encouraging milieu in which an interdisciplinary approach with the teamwork of an endodontist, periodontist and physician has brought about both clinical and radiographic improvement in endo-perio lesions present in chronic hepatitis patients.

Conflict of interest

Nil

References

1. Simring M, Goldberg M. The pulpal pocket approach: Retrograde periodontitis. *J Periodontol* 35 (1964): 22-48.
2. Mazur B, Massler M. Influence of periodontal disease on the dental pulp. *Oral Surg Oral Med Oral Pathol Oral Radiol Endod* 17 (1964): 592-603.
3. Simon JH, Glick DH, Frank AL. The relationship of endodontic periodontic lesions. *J Periodontol* 43 (1972): 202-208.
4. Tsesis I, Faivishevsky V, Kfir A, et al. Outcome of surgical endodontic treatment performed by a modern technique: a meta-analysis of literature. *J Endod* 35 (2009): 1505-1511.
5. Golla K, Epstein JB, Cabay RJ. Liver disease: current perspectives on medical and dental management. *Oral Surg Oral Med Oral Pathol Oral Radiol Endod* 98 (2004): 516-521.
6. Kim S, Kratchman S. Modern endodontic surgery concepts and practice: a review. *J Endod* 32 (2006): 601-623.
7. Hattar S, Berdal A, Asselin A, et al. Behaviour of moderately differentiated osteoblast-like cells cultured in contact with bioactive glasses. *Eur Cell Mater* 31 (2002): 61-69.
8. Bottino MC, Thomas V, Schmidt G, et al. Recent advances in the development of GTR/GBR membranes for periodontal regeneration-a materials perspective. *Dent Mater* 28 (2012): 703-721.
9. Dohan DM, Choukroun J, Diss A, et al. Platelet-rich fibrin (PRF): a second-generation platelet concentrate. Part I: technological concepts and evolution. *Oral Surg Oral Med Oral Pathol Oral Radiol Endod* 101 (2006): 37-44.
10. Panda S, Sankari M, Satpathy A, et al. Adjunctive effect of autologous platelet-rich fibrin to barrier membrane in the treatment of periodontal intrabony defects. *J Craniofac* 27 (2016): 691-696.



This article is an open access article distributed under the terms and conditions of the [Creative Commons Attribution \(CC-BY\) license 4.0](https://creativecommons.org/licenses/by/4.0/)