INTERNATIONAL JOURNAL OF APPLIED BIOLOGY AND PHARMACEUTICAL TECHNOLOGY

www.ijabpt.com Volume-5, Issue-3, July-Sept -2014 Coden : IJABPT Copyrights@2014

ISSN : 0976-4550

Received: 4th May 2014 *Revised: 27th May-2014* *Accepted: 28h May-2014*

Research Article

LEAD ACETATE INDUCED HISTOPATHOLOGICAL ALTERATIONS IN RENAL TISSUE OF BALB-C MICE (*MUS MUSCULUS)*

Sushma Sharma[a] and Balbinder Singh*

Department of Bio-Sciences, Himachal Pradesh University, Shimla-171005, INDIA
E-mail: sushma_bio_sci@rediffmail.com

ABSTRACT: The aim of the study was to evaluate the histological alterations induced by lead intoxication in the mice kidney. Eighteen mice (20-24g body weight) were divided into 3 groups of 6 animals each. First group served as control and was given normal saline solution as vehicle. The second and third groups were orally administered (10 and 150 mg/kg body weight) lead acetate respectively for 40 days. After 40 days of lead acetate treatment, 3 mice from each group were sacrificed and the rest were left for 80 days without any supplement. Kidneys were excised for histological studies. The findings indicated that chronic exposure to subtoxic concentrations of lead acetate produced progressive tubular, glomerular and interstitial damage that include tubular dilation, vacuolar degeneration, atrophy of glomerular tuft, interstitial edema and congestion of blood capillaries. Lesions were more pronounced in animals exposed to high dose. However mice at 80 days showed improvements in lead induced histopathological alterations. The severity of lesions of lead toxicity depends on the dose of lead and period of exposure.

Key words: Lead acetate, oxidative stress, kidney.

INTRODUCTION

Lead is one of the most encountered toxic metal that induces a broad range of physiological, biochemical and neurological dysfunctions in humans (Skerfving *et al.,* 2007). The main sources of lead exposure in developing and industrialised countries include gasoline additives, lead based paints, leaded batteries, cosmetics and plastic recycling industries (Hurst *et al*., 2004; Mudipalli, 2007). In Nigeria, the main sources of lead pollution is through automobile exhaust because of the use of the leaded petrol. Tetra ethyl lead is commonly used as an anti-knocking additive to improve the quality of petrol in Nigeria and many other countries (Kamal *et al.,* 1998). Research has also shown that lead is present in tobacco. Cigarettes contain 2.4µg of lead and 5% of this occurs in ash and side stream smoke (Mussalo *et al.,* 1986). There is experimental evidence to indicate that cellular damage mediated by reactive oxygen species can be involved in the pathology associated with lead toxicity (Eercal *et al.,* 2001; Bolin *et al.,* 2006). Lead is known to cause oxidative damage in several tissues by bringing about imbalance in the generation and removal of reactive oxygen species (Upasani *et al.,* 2001; Sharma *et al.,* 2010). Many animal studies have shown that lead is capable of causing oxidative stress in kidney, liver and brain (Ercal *et al.,* 2001; Patra *et al.,* 2001). The absorbed lead is conjugated in the liver and passed to the kidney, where a small quantity is excreted in urine and rest accumulates in various body organs and affects many biological activities at the molecular, cellular and intercellular levels, which may result in morphological alterations that can remain even after lead levels have fallen (Jarrar, 2003; Sidhu *et al*., 2004; Taib *et al.,* 2004; Flora *et al.,* 2006). As kidney is a common target organ for injury from exposure to a broad range of chemicals and drugs, the present study is an attempt to characterize histological alterations induced by lead in the kidney of Swiss albino mice with a trial to evaluate their self recovery from this toxicant without any supplement.

MATERIALS AND METHODS

Laboratory mice

Eighteen sexually mature Swiss-albino mice of Balb-C strain weighing 20-24g were utilized in the present study. The mice were procured from the Central Research Institute (CRI), Kasauli, Himachal Pradesh (India). They were kept for two weeks in a pathogen free, well ventilated room in the departmental animal house in order to enable them to acclimatize to their environment.

During the period of experiment, the animals were supplied with food pellets and drinking water on daily basis and their beddings were changed, discarded and disinfected. All experiments were conducted after the approval of Institutional Animals Ethics Committee, Himachal Pradesh University (IAEC /BIO/7-2011), Shimla (India).

Chemicals

Lead acetate [$(CH_3COO)_2$ Pb.$3H_2O$] was purchased from Sigma Chemical Co. (St. Louis, MO, USA). All other chemicals used in the experiment were of analytical grade.

Experimental design

Adult Swiss-albino mice were divided into three groups of 6 mice each. Group 1 served as control, received normal saline solution. Group 2 and group 3 were given lead acetate at a dose of 10 mg/kg bw and 150 mg/kg bw respectively by oral gavage once daily for 40 days. Three mice from each group were sacrificed after day 40 and 80 under light chloroform anaesthesia.

Histopathological analysis

Kidney was quickly removed, washed in normal saline solution and immersed in 10% formalin at room temperature for 72 hrs. After fixing the tissue, it was thoroughly washed under running water and dehydrated in ascending grades of ethyl alcohol, cleared and then embedded in paraffin wax. Tissue sections of 5µ were obtained, stained by haematoxylin and eosin (H&E) and evaluated under light microscope. However images representing the typical histopathological profile in control and treated groups were captured with the aid of Leica microscope.

RESULTS

The kidney tissues of control group showed normal architecture of both renal corpuscles and tubules. The tubules were well arranged, uniformly stained and were lined with regular thick cubical epithelium. Tubular epithelial cells of proximal convoluted tubules and distal convoluted tubules also exhibited normal rounded nuclei. Corticomedullary region was clearly demarcated and showed normal rounded glomeruli without any signs of damage (Fig. 1 and 2).

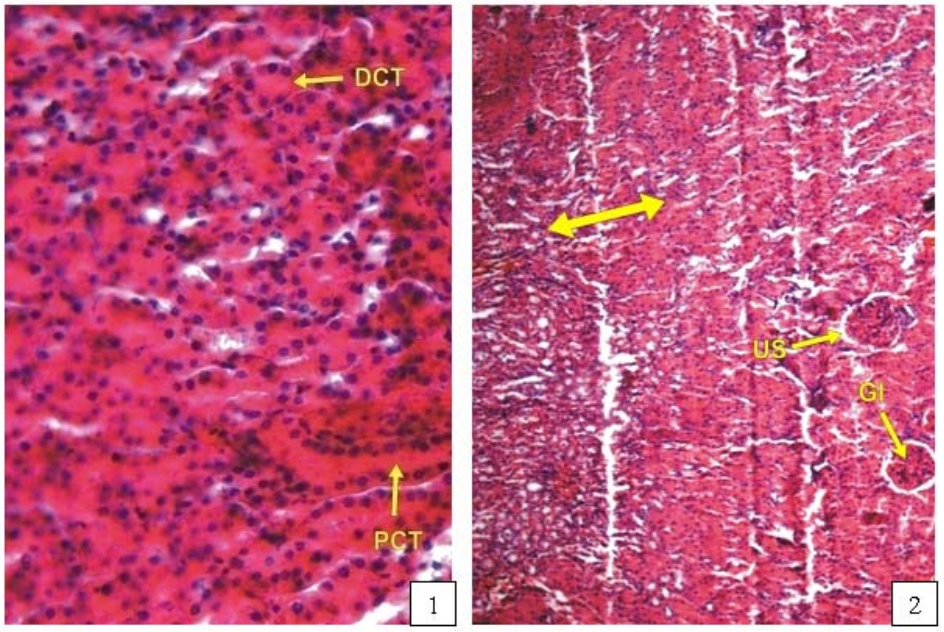

Fig. 1: Section from control mice kidney showing normal proximal (PCT) and distal convoluted tubular (DCT) epithelium (H&E 400X).

Fig. 2: Section from control mice kidney exhibiting normal glomerulus (Gl) with urinary space (US) and demarcated corticomedullary region (↕) with medullary rays (H&E 100X).

Histological changes in mice kidney exposed to low dose of lead (10 mg/kg bw) for 40 days were seen (Fig. 3 and 4). The lesions were in the form of mild granular and vacuolar degeneration in tubular epithelial cells, some cells showed focal necrosis, atrophy of glomerular tuft and dilation of bowman's space. However the incidence and severity of these histopathological changes increased by increasing the dose, where the kidney of group treated with 150 mg/kg bw lead acetate, demonstrated extensively atrophied glomerulus, increased periglomerular space, MNC's infiltration in interstitial space, haemorrhages, cell debris in tubular lumen and desquamated renal tubular epithelium in focal areas. Sections of lead acetate treated mice kidneys at 40 days stage also revealed pyknosis in some epithelium lining cells in the proximal tubules with lesser extent in distal ones. This alteration was seen more severe at 40 days stage than 80. Furtheremore pyknotic nuclei were seen mainly in necrotic renal cells with occational anisokaryosis, karyomegaly and karyolysis were seen mainly in the proximal convoluted tubules (Fig. 5 and 6).

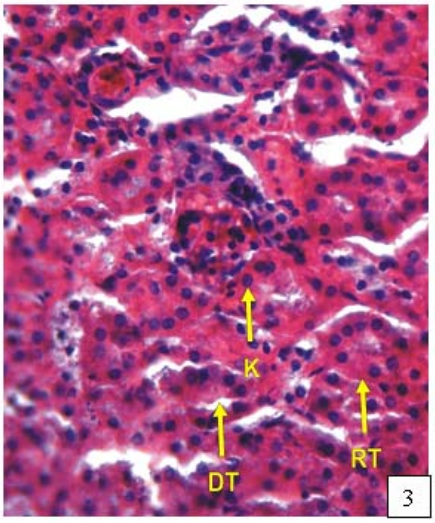

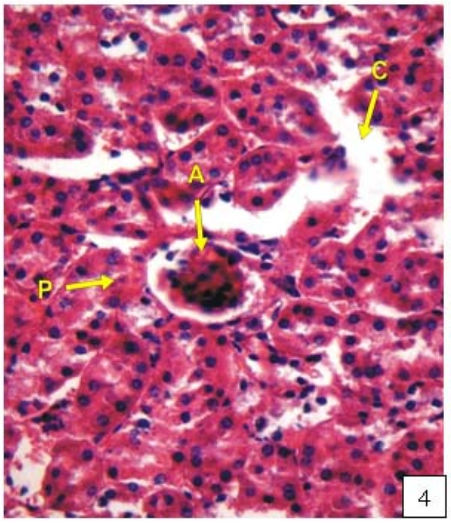

Fig. 3: Section from mice kidney treated with 10 mg/kg bw lead acetate for 40 days showing vacuolar degeneration (VD). Necrosis (N) and karyomegaly (K) of tubular epithelial cells (H&E 400X).
Fig. 4: Section from mice kidney treated with 10 mg/kg bw lead acetate for 40 days demonstrating atrophy of glomerular tuft (A), loss of cortical (C) tissues and pyknotic nuclei in necrotic tubular cells (H&E 400X).

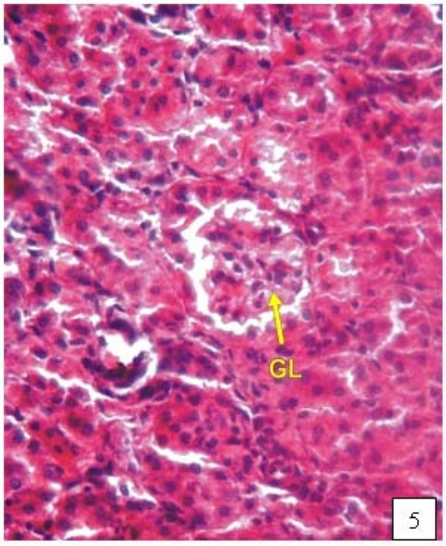

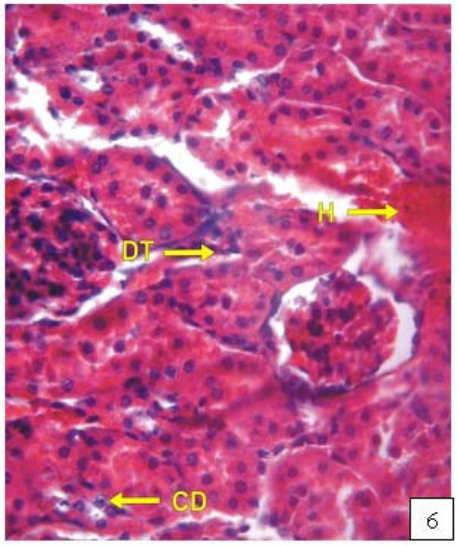

Fig. 5: Section from mice kidney treated with 150 mg/kg bw lead acetate for 40 days depicting extensively atrophied glomerulus (Gl) with increased periglomerular space (H&E 400X).
Fig. 6: Section from mice kidney treated with 150 mg/kg bw lead acetate for 40 days exhibiting pockets of haemorrhages (H), cell debris (CD) in tubular lumen and desquamated tubular (DT) epithelium in focal areas (H&E 400X).

Examination of mice kidney treated with lead acetate doses (10 mg/kg bw and 150 mg/kg bw), at 80 days stage, after withdrawal of both doses at 40 days revealed that most of these histopathological changes were improved. In low dose (10 mg/kg bw) treated group, the renal tissue restored most of its normal structures. Corticomedullary region was clearly demarcated and showed some normal rounded glomeruli without damage at any spot. Most of tubules appeared compactly arranged, rounded, but at places were thin walled. No inclusion of inflammatory cell infiltration was evident (Fig. 7 and 8). However mice group treated with high dose lead acetate (150 mg/kg bw) showed slight edema and vacuolation of some tubular cells. Some tubules appeared normal. Some congested glomeruli with wide urinary space were also reported. Inclusion of blood cells was also evident. However lost cortical region was not recovered completely even at the end of 80 days (Fig. 9 and 10).

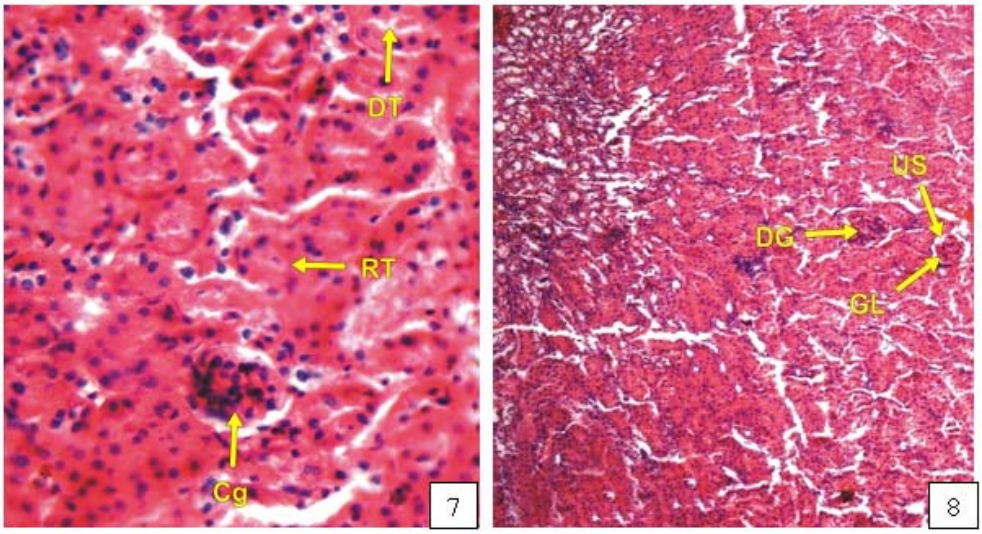

Fig. 7: Section from low dose treated mice kidney at 80 days stage after withdrawal of lead acetate at 40 days stage showed congested glomerulus (Cg) regenerated tubules (RT) with some degenerated tubules (DT) and maximum regenerated cortical region (H&E 400 X).

Fig. 8: Section from low dose treated mice kidney at 80 days stage after withdrawal of lead acetate at 40 days stage demonstrated normal round glomerulus (GL) with urinary space (US), damaged glomerulus (DG) and well demarcated corticomedullary region. (H&E 100X).

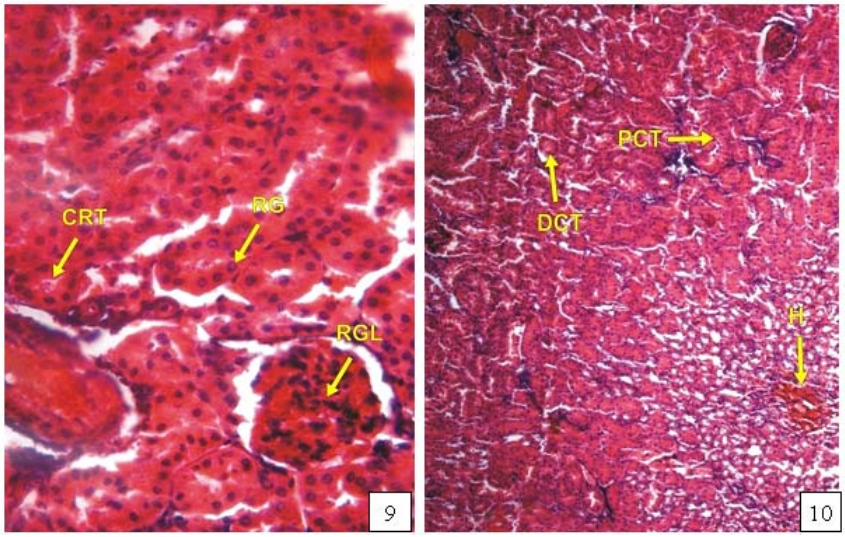

Fig. 9: Section from high dose treated mice kidney at 80 days stage after withdrawal of lead acetate at 40 days stage depicted nearly regenerated glomerulus (RGL), some completely regenerated tubules (CRT), with a few in a regenerating (RG) stage and nearly regenerated Cortical region (H&E 400X).

Fig. 10: Section from high dose treated mice kidney at 80 days stage after withdrawal of lead acetate at 40 days stage exhibited regenerated proximal (PCT) and distal convoluted tubules (DCT). Intertubular haemorrhages (H) in medular region was also noticed (H&E 100X).

DISCUSSION

The results of the present work showed that sub-toxic chronic lead exposure resulted in progressive tubular, glomerular and interstitial alterations. Some of these findings are in agreement with results of previous investigations (Lilis *et al.,* 1980; Hine *et al.,* 1981; linet *et al.,* 1993). The varieties of histological alterations of the renal tissues due to lead intoxication by different investigators could be due to the variations in the level of exposure, duration, route of administration and animal species used in the experiments (Ceruti *et al.,* 2002). The data of present work demonstrated that cortex is more affected than medulla due to long-term treatment with lead. This could be due to uneven distribution of lead in the tissue of kidney where about 90% of the total renal blood flow enters the cortex via the blood stream. Therefore, a relative high lead concentration might reach the cortex via blood stream than that would enter the medulla (Jarrar *et al.,* 2001). The results of present work exhibited that tubular changes occur earlier than glomerular and interstitial changes. Moreover, tubular damages were more prominent in proximal convoluted tubules (PCT's) than distal (DCT) convoluted tubules (Moreira *et al.,* 2001; Adeniyi *et al.,* 2008). This could be due to the fact that the PCT's are the primary sites of reabsorption and active transport leading to higher concentration of lead in the epithelial lining of these tubules (Jarrar *et al.,* 2007). Necrosis, tubular vacuolization and tubular dilation found in our results due to lead intoxication were also reported by other workers (Diamond, 2005). These tubular alterations due to lead toxicity might be a result of hydraulic changes in renal tissue and suggest that lead intoxication yields to a partial failure in the ion pump transport of tubular cells, which in turn produces tubular swelling and causes necrosis and vacuolization of tubules (Senapati *et al.,* 2001; Bellinger, 2008; Sharma *et al.,* 2011). Also, these changes might indicate incapability of renal cells to deal with accumulated residues resulting from metabolic and structural disturbances caused by lead. Our results also demonstrated that the incidence and severity of histopathological changes increased with increasing dose, where the kidney of high dose treated mice showed extensively atrophied glomerulus with increased perivascular space, MNC's infiltration in interstitial space, haemorrhages and cell debris in tubular lumen (Aviv *et al.,* 1980; Dieter *et al.,* 1993; Khalil-Manesh, 1992). The histopathological lesions described above confirm to the generally accepted classification of tubulo-interstitial nephritis. The pattern which emerges in the lead exposed mice is that of a progressive nephrotic syndrome affecting first tubules and surrounding blood vessels with secondary to a glomerular lesions involving the epithelial cells and capillary loops. In conclusion, lead acetate toxicity results in alterations in the renal tubular and glomerular cells, which could play an important role in renal dysfunction.

CONCLUSION

The findings of this study indicated that chronic exposure to sub-lethal doses of this toxicant induced marked glomerular, tubular and interstitial alterations in the renal tissue. This severity depends on the concentration and prolonged period of exposure.

ACKNOWLEDGMENT

One of the Authors duly acknowledged and thanks the Council of Scientific and Industrial Research, New Delhi for the award of Junior Research Fellowship (JRF).

REFERENCES

Adeniyi, T. T., Ajayi, G. O and Akinloye, O. A. (2008). Effect of Ascorbic acid and *Allium sativum* on tissue lead in female *Rattus norvegicus.* Nijer. J. Health Biomed. Sci. 7(2): 38-41.

Aviv, A., John, E. and Bernstein, J. (1980). Lead intoxication during development: Its late effect on kidney function and blood pressure. Kidney Int. 17: 430-437.

Bellinger, D. C. (2008). Very low lead exposures and children's neurodevelopment. Current Opinion in Pediat. 2: 172-177.

Bolin, C.M., Basha, R., Cox, D., Zawia, N. H., Maloney, B., Lahiri, D. K and Cardozo Pelage, F. (2006). Exposure to lead and the developmental origin of oxidative DNA damage in the aging brain. FASEB J. 20: 788- 790.

Ceruti, R., Ghisleni, G., Ferretti, E., Cammarata, S., Sonzogni, O. and Scanziani, E. (2002). Wild rats as monitors of environmental lead contamination in the urban area of Milan, Italy. Environ. Pollut. 117(2): 225-9.

Diamond, G. L. (2005). Risk assessment of nephrotoxic metals. The toxicology of the kidney. London: CRC Press, pp. 1099-1132.

Dieter, M. P., Matthews, H. B. and Jeffcoat, R. A. (1993). Comparison of lead bioavailability in F344 rats fed lead acetate, lead oxide, lead sulphide, or lead ore concentrate from Skagway, Alaska. J. Toxicol. Environ. Health. 39: 79-93.

Ercal, N. H., Gurer-Orhan and N. Aykin-Burns, (2001). Toxic metals and oxidative damage. Curr. Top. Med. Chem. 1: 529-539.

Flora, S. J. S., Flora, G. and Saxena, G. (2006). Enviormental occurrence, health effects and management of lead poisoning. In*:* Lead: chemistry, analytical aspects, environmental impact and health effects. Casas, J.S. & Sordo, J.(Eds.). Amsterdam, Elsevier science, pp. 158-228.

Hine, C. H., Lewis, H. A., Northrup, J, Halls, S. and Embree, J.W. (1981). Kidney function in lead workers. In*:* Environmental lead. Lynam DR, Piantanida, L, Colle, JF, eds. Academic press, New York, 231-252.

Hurst, H. E. and Martin, M. D. (2004). Toxicology. In Yagiela, J. A.; Dowd, F. I.; Neidle, E. A. Pharmacology and Therapeutic for Dentistry. 5th Edn, Mosby, USA, pp. 829-848.

Jarrar, B. M. (2003). Histological and Histochemical alterations in the kidney induced by lead. *Ann. Saudi Med.* 23 (1-2): 10-5.

Jarrar, B. M. and Mahmoud, Z. N. (2000). Histochemical characterization of the lead intranuclear inclusion bodies. Biol. Tr. Elem. Res, 74: 1-7.

Kamal, K. and Kumar, B. D. (1998). Lead Toxicity. Indian Pediatr. 35: 209-216.

Khalil-Manesh, F, Gonick, H. C. And Cohen, A. H. (1992). Experimental model of lead nephropathy. I. Continuous high-dose lead administration. Kidney Int. 41: 1192-1203.

Lils, R., Fischbein, A, Vulciukas, J. A, Blumberg, W. and Selikoff, I. J. (1980). Levels of renal function impairment in lead exposed workers. Correlations with zinc protoporphyrin and blood lead levels. Dev.Toxicol. Environ. Sci. 8: 363-370.

Lin, J. L., Yeh, k. H., Tseng, H.C., Chen, W.Y., Lai, H. H, and Lin, Y. C. (1993). Urinary N-Acetyl-glucosaminidase excretion and environmental lead exposure. Am. J. Nephrol. 13: 442-447.

McGavin, M. D. and Zachary, J. F. (2007). Pathologic basis of veterinary disease. 4th ed. St. Louis, Mosby, pp. 654-5.

Moreira, E. G. Vassilieff, V. S. (2001). Development lead exposure. Behavioural alterations in the short and long term. Neurotox. Teratol. 23: 489-495.

Mudipalli, A. (2007). Lead Hepatotoxicity and Potential Health Effects. Indian Journal of Medical Research, 126: pp. 518-527.

Mussalo-Rauhmaa, H., Salmela, S. S., Leppanen, A. and Pyassalo, H. (1986). Cigarettes as a source of some trace and heavy metals in man. Arch. Environ. Health 41: 49-55.

Patra, R., Swarup, D. and Dwivedi, S. (2001). Antioxidant effects of tocopherol, ascorbic acid and L-methionine on lead induced oxidative stress on the liver, kidney and brain in rats. Toxicology. 162: 81-8.

Senapati, S. K., Dey, S., Dwivedi, S. K., Swarup, D. (2001). Effect of garlic (*Allium sativum L.*) extract on tissue lead level in rats. J. Ethnopharmacol. 76: 229-232.

Sharma, V., Sharma, A. and Kansal, L. (2010). The effect of oral administration of Allium sativum extracts on lead nitrate induced toxicity in male mice. Food. Chem. Toxicol. 48: 928-936.

Sharma, V., Sharma, S., Pracheta, Paliwal, R and Sharma, S. H. (2011). Therapeutic efficacy of *Withania somnifera* root extract in the regulation of lead nitrate induced nephrotoxicity in swiss albino mice. J. Pharm. Res. 4: 755-758.

Sidhu, P. and Nehru, B. (2004). Lead intoxication: Histological and oxidative damage in rat cerebrum and cerebellum. J. Trace Elem.Exp. Med. 17(1): 45-53.

Skerfving, S. and Bergdahl, I. A. (2007). Handbook on the toxicology of metals.3rd ed. Amsterdam, Academic Press, pp. 599-643.

Taib, N. T., Jarrar, B. M. and Mubarak, M. (2004). Ultrastructural alterations in hepatic tissues of white rats (*Rattus norvegicus)* induced by lead experimental toxicity. Saudi J. Biol. Sci. 11(1): 11-20.

Upasani, C. D., Khera, A and Balaraman, R. (2001). Effect of lead with Vitamins E, C, or Spirulina on malondialdehyde: conjugated dienes and hydroperoxides in rats. Ind. J. Exp. Biol. 39: 70-74.