

A STUDY OF EARLY DIVISION OF RENAL ARTERY AND THEIR INCIDENCE

*Naveen Kumar.S, *Atoofa jaleel and *JV Sireesha

*Department of Anatomy, Dr VRK Women's Medical College & Research Institute, Hyderabad

ABSTRACT: The knowledge of arterial supply of the human kidney is of special interest as it is not only having many morphological variations but also many vascular surgeries are carried out in case of renal artery. The present study was done in 50 embalmed cadavers during the period of one year. We found variations in the form of the number of renal artery supplying the kidney, its level of origin, relation with the renal vein, branching pattern. Knowledge of these variations may help to avoid the clinical complications especially during radiological examinations and/or surgical approaches in this region.

Keywords: Renal artery, Renal vein, variations in renal artery

INTRODUCTION

Kidneys are essential organs of excretion. They represent less than 1/100th of the total body weight and receives blood supply by renal arteries. The blood received by the kidneys constitutes 20% of cardiac output. Renal arteries supply the kidneys by dividing into segmental, lobar, interlobar and arcuate arteries. The terminal branches are end arteries as they do not anastomose. A single artery to each kidney is present in approximately 80% of individuals (Williams PL, et al., 2008). However variations of the renal arteries in level of origin, their caliber, obliquity and precise relations have been found by research workers in the past (Gupta A, et al., 2011 and Graves FT, et al., 1956). The presence of anomalous branching pattern of the renal arteries is not uncommon in 70% of cases; there is a single renal artery each kidney (Hellstrum J, et al., 1927). Considering this fact, multiple branching pattern is uncommon finding and need to be given due attention. Multiple branching patterns may result in altered haemodynamic and inadvertent injury during surgery. In present study, we reported anomalous branching pattern of the renal arteries, may be important from academic and clinical view point.

METHODS

The present study was done on 50 embalmed cadavers during routine dissection practices for undergraduates in the dissection hall of Gandhi Medical College, Secunderabad and Osmania Medical College, Hyderabad. A vertical incision was given from xiphoid process to pubic symphysis. One horizontal incision was given from xiphoid process laterally to the body. Another horizontal incision was given from pubic symphysis to iliac crest. Skin flaps were reflected laterally. Anterior abdominal wall muscles, rectus muscles and their aponeurosis were identified and reflected. Abdominal cavity was opened by reflecting the peritoneum. Greater omentum was identified and it was reflected. Duodenum and Pancreas were reflected. Small intestines were turned to left. Fat and fascia from the anterior surface of left kidney and suprarenal gland were exposed and were removed. The left Suprarenal vein and the testicular vein (Ovarian vein) were traced to left renal vein. Renal vein was displaced to expose the left renal artery. Its branches to left suprarenal gland and ureter were identified. Left kidney was turned medially to expose its posterior surface and there relation of posterior surface of kidney were studied. The similar procedure was carried out on the right side to expose the right kidney.

RESULTS

In the present study among 50 cadavers dissected, in one case, on the right side, the renal arteries as found to have originated from the abdominal aorta and it soon divided into two branches which supplied the hilum. In another cases on the left side, we found the renal arteries dividing much before the hilum. In one case four anterior branches and one posterior branch to the renal vein were seen. In another case three anterior and one posterior branch were found in relation to the renal vein. In third case wherein three anterior branches and one posterior branch to the renal vein were observed. Normally the renal vein is anterior most structure at the hilum. Considering just one case as early division. (Figures 1 to 5).

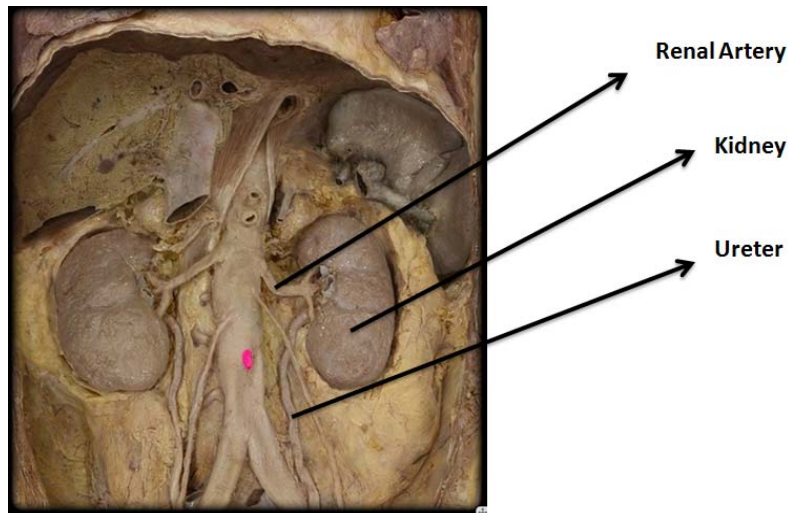


Figure 1: Normal kidneys in a cadaver

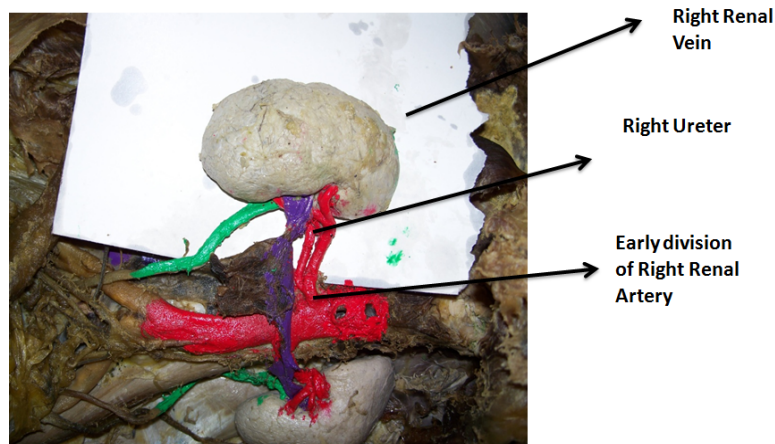


Figure 2: Early division of right renal artery

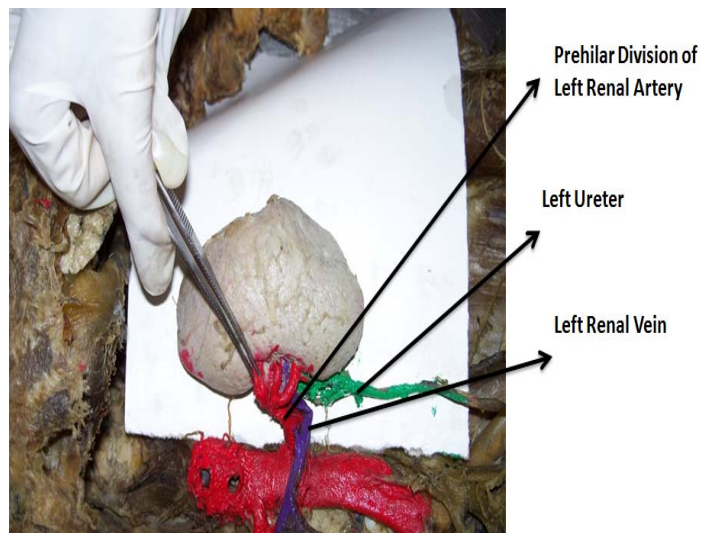


Figure 3: Prehilum division of left renal artery

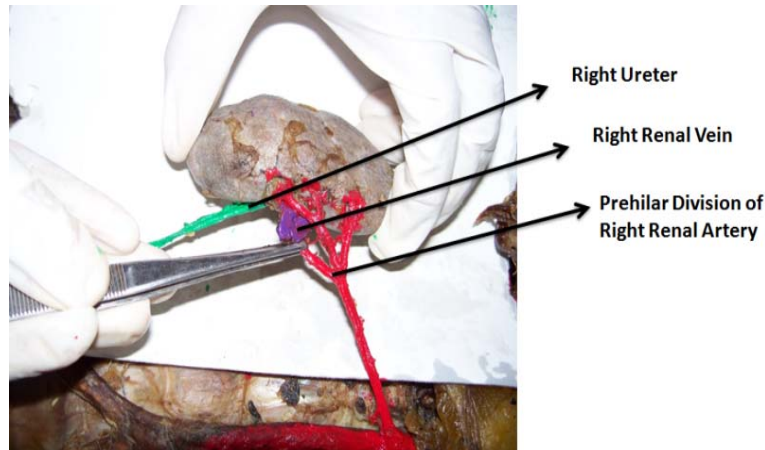


Figure 4: Prehilar division of right renal artery

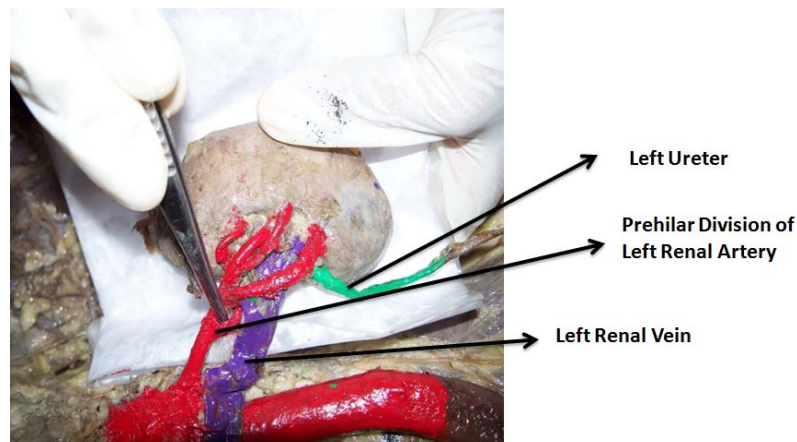


Figure 5: Another prehilar division of left renal artery

DISCUSSION

Vasculature of kidney is indeed an important topic for all medical and surgical specialties. About 20% of cardiac output passes through the kidneys and is filtered. The renal arteries normally are two in number, one to each kidney. Each artery normally enters the kidney at its hilum and divided into five segmental branches. However variations have been seen in the number of arteries supplying the kidney, their branching pattern and their relation to the other structures at the hilum. Lack of knowledge of such variations could lead to serious complications while performing surgical procedures. Diagnosis of such variations is quite simple with the availability of angiography. By the use of this equipment it is indeed difficult to miss any type of anomaly of the blood vessels anywhere in the body. Aberrant renal arteries were observed at early 1552 by Eustachius B (Ozkan U, et al., 2006), but surprisingly this work was unnoticed for a long time. About two centuries later i.e in 1714 it was found in the Papal library printed on plates. This was brought to the notice of scientists much later by Graves FT, in the year 1956. In his article titled "The aberrant renal artery", Graves FT, had mentioned works of several scientists who reported aberrant blood supply to the kidney (Graves FT, et al., 1956). Cited in the article is a study by Hellstrom in 1927 which said 50% of the cases studied by him had aberrant blood supply to the kidney (Shakeri AB, et al., 2007)

In the year 2006 Ozkan U et al, study reported early division of renal arteries in 8% of the cases observed by them (Standing S, et al., 2005). In the year 2007 Shakeri AB et al, found in a 30 year old male, left sided renal artery which soon divided in to two branches after arising from the aorta viz. upper and lower pole (Williams PL, et al., 2008). Another renal artery on the same side was seen to originate from abdominal aorta and divided in to two anterior and one posterior artery which entered the hilum.

A total of 5 branches entered the kidney namely viz. one to the upper pole, one to the lower pole, two anterior and one posterior. These being the normal segmental branches of the renal artery, it can be considered as early division. The variation from the normal here is that instead of a single renal artery, two arteries arose from the abdominal aorta. One contributed to the supply of the poles whereas the other supplied the posterior and the anterior aspect.

In the present study accessory arteries were seen in two cadavers out of the 50 cadavers dissected. The incidence of early division in the present study was therefore 2 %.

CONCLUSION

To conclude, the study of renal artery variations is a vast subject, which has to be dealt in a more exhaustive way. In the present work, accessory renal arteries were the commonest variations observed. The other variations were early division of the renal arteries. The present study is a humble beginning in evaluating the various renal artery anomalies. There is definite need to pursue further the present work in order to reach its destined goal of enlightening the medical fraternity about these variation and their outcome. Surely renal artery anomalies may be associated with other medical/genetic disorders. The present worker is confident of extending this work, with the help of modern medical procedures try to establish such associations.

REFERENCES

- Williams PL, Bannister LH, Berry MM, Collins P, Dyson M, Dusse KJE (2008). Gray's Anatomy. 40th ed. London: Churchill, Livingstone; 1231.
- Gupta A, Gupta R, Singhla RK. (2011). The Accessory Renal Arteries: A Comparative Study in Vertebrates with Its Clinical Implications. *J Clin Diagn Res* 5:970-3.
- Graves FT. The aberrant renal artery. *J Anat* 1956; 90:553-8.
- Standing S (Ed) (2005). Grays Anatomy, The anatomical basic of clinical practice. London, Elsevier, Churchill Livingstone Publishers, 1274 – 1275.
- Eustachius, B; (1714) *Tabulae Anatomicae. Tab. Tertius, Id. Lancisi: Rome.* (Graves FT; The aberrant renal artery. *J Anat.*1956; 90:553.
- Hellstrom, J. (1927). A contribution to the knowledge of the relation of abnormally running renal vessels to hydronephrosis, and an investigation of the arterial conditions in fifty kidneys. *Acta chir. Scand.* 61, 289-330.
- Ozkan U, ODuzkurt L, Tercan F, Kizilkili O, Kole Z, Koca N. (2006). Renal artery origins and variations: angiographic evaluation of 855 consecutive patients. *Diagn Interv Radiol.* Dec; 12(4):183-6.
- Shakeri AB, Shane Tubbs R, Shoja MM, Pezeshk P, Farahani RM, Khaki AA, Ezzati F, Seyednejad. (2007) Bipolar supernumerary renal artery. *Surg Radiol Anat.* Feb; 29(1):89-92.