



PROTECTIVE EFFECT OF *FAGONIA ARABICA* (L.) AGAINST ISOPROTERENOL INDUCED MYOCARDIAL INFARCTION IN ALBINO WISTAR RATS

K.R. Dase Gowda¹, E. Maruthi Prasad², S.B.Md. Rahmathulla³, Lakshmi Devi Kodidhela^{2*}

¹Department of Biotechnology, New Horizon College of Engineering, Bangalore, India


²Department of Biochemistry, Sri Krishnadevaraya University, Anantapur-515003, India

³Department of Biomedical Sciences, Adigrat University, Ethiopia.

ABSTRACT: The present study was designed to investigate the cardioprotective effect of *Fagonia arabica* against Isoproterenol (ISO) induced myocardial infarction (MI) in rats by studying myocyte injury markers, antioxidant defense system, serum and heart lipid profile, inflammatory markers, electrocardiographic and histopathological changes. MI in rats was induced by ISO administration (85 mg/kg, s.c.) at an interval of 24 h on 31st and 32nd day. On 33rd day ECG, biochemical and histopathological parameters were assessed. ISO administration showed changes in ECG pattern, including ST-segment elevation (diagnostic of myocardial infarction) increase in the serum levels of cardiac injury markers (creatin kinase-MB, lactate dehydrogenase, aspartate transaminase and alanine transaminase), decreased antioxidant defense system in the heart and altered lipid profile in the serum and heart. Results of the present study suggest that *F.arabica* has a significant effect on the protection of the heart against ISO induced MI through maintaining endogenous antioxidant enzyme activities.

Key words: Myocardial infarction, Antioxidant, lipid metabolism, Electrocardiography

*Corresponding author: Prof. K. Lakshmi Devi, Department of Biochemistry, Sri Krishnadevaraya University, Anantapuramu-515003, India E-mail klakshmidivbio@gmail.com

Copyright: ©2016 Prof. K. Lakshmi Devi. This is an open-access article distributed under the terms of the Creative Commons Attribution License , which permits unrestricted use, distribution, and reproduction in any medium, provided the original author and source are credited

INTRODUCTION

MI is the common presentation of the ischemic heart disease. It occurs when myocardial ischemia surpasses the critical threshold level for an extended time resulting in irreversible myocardial cell damage. Although clinical care is improved, public awareness is raised and health innovations are widely used, myocardial infarction still remains the leading cause of death worldwide (Kareem et al., 2013). According to the World Health Organization it will be the major cause of death in the world by the year 2030 (Maruthi et al., 2015). In India, the number of patients being hospitalized for myocardial infarction, commonly known as heart attack, is increasing over the past 35 years and male patients have shown a more striking increase (Mosca et al., 1997).

Isoproterenol (ISO) [1- (3,4- dihydroxyphenyl) -2 -isopropylamino ethanol hydrochloride] is a synthetic catecholamine and β -adrenergic agonist, which has been documented to produce severe stress in the myocardium resulting in the myocardial infarction, if administered in supramaximal doses (Shaik et al., 2012). It produces myocardial necrosis which caused cardiac dysfunction, increased lipid peroxidation along with an increase in the level of myocardial lipids, altered activities of the cardiac enzymes and antioxidants (Rahmathulla et al., 2012). The pathophysiological and morphological aberrations produced in the heart of this myocardial necrotic rat model are comparable with those taking place in human myocardial infarction (Pfeffer et al., 1991). Among the various mechanisms proposed to explain the ISO induced cardiotoxicity, generation of highly cytotoxic free radicals through auto-oxidation of catecholamines has been implicated as one of the important causative factors. Free radicals and reactive oxygen species have been implicated in large number of diseases and have a deleterious effect on heart functioning.

Various experimental and clinical studies have shown that enormous amount of reactive oxygen species such as, superoxide, hydrogen peroxide and hydrogen radicals are generated in failing myocardium (Krushna et al., 2012). Therefore, therapeutic interventions having antioxidants or free radical scavenging activity may be useful against oxidative stress associated with various cardiovascular diseases including myocardial infarction. Genus *Fagonia* belongs to family zygophyllaceae & comprises 35 different species, various studies showed variety of *Fagonia* species possesses medicinal properties. *F.arabica* is commonly known as 'Kharasan' thorn in English and 'Dhamasa' in India. It is a green shrub, one to three feet in height, found on calcareous rocks found throughout the Mediterranean region of South Africa, Afghanistan, and distributed in different states of India, Rajasthan, Gujarat, and Maharashtra. Several phytochemicals reported are diterpenes, triterpenoid, saponins, fagonone and its derivatives, besides flavonoids and sterol glycosides (Fahn and Carmela, 1996; Patel et al. 2012). *F.arabica* showed antioxidant activity, free radical scavenging ischemic oxidative stress, atherothrombotic, diuretic, Anti-inhibitory for lipases & pancreatic lipase (Ageely et al., 2014).

The present study aimed to evaluate the possible protective mechanisms of therapeutic efficacy of *F.arabica* by studying the biochemical markers, antioxidant defense system, lipid profile, electrocardiographic and histopathological changes.

MATERIALS AND METHODS

Plant Extract

Freshly collected *F. arabica* whole plant was dried under shade and the dried material was milled to obtain a coarse powder. The alcoholic extract of the powder was prepared by the process of continuous extraction (Soxhlation), such that 1g of alcoholic extract equivalent to 5g of crude drug was obtained (Raghavendra et al., 2010).

Animals

All experiments and protocols described in present study were approved by Animal Ethics Committee and with permission from Committee for the Purpose of Control and Supervision of Experiments on Animals (Regd. No. 470/01/a/CPCSEA) of Sri Krishnadevaraya University, Anantapur. Four week old male albino wistar rats (100-120 g) were housed and maintained under standardized conditions (12-h light/dark cycle, 24 ± 2 °C, 35 to 60% humidity) and provided free access purified drinking water ad libitum.

Induction of MI

ISO was dissolved in normal saline and injected to rats (85mg/kg) at an interval of 24 h for 2 days to induce experimental myocardial infarction.

Experimental design

After acclimatization, the animals were randomly divided into the following groups consisting of 8 rats in each group.

Group 1- Normal control untreated rats receives saline for 30 days.

Group 2-Saline for 40 days and two doses ISO 85 mg kg⁻¹ bw in the end

Group 3-Losartan treated 40 mg kg⁻¹ bw for 07 days and two doses of ISO 85 mg kg⁻¹ bw

Group 4-*F.arabica* extract low dose (FAEtLd) of 250 mg kg⁻¹ bw for 40 days and two doses of ISO 85 mg kg⁻¹

Group 5-*F.arabica* extract of high dose (FAEtHd) of 500 mg kg⁻¹ bw for 40 days and two doses of ISO 85 mg kg⁻¹

Biochemical analysis

After recording the ECG, the animals were sacrificed and blood samples were collected. Serum was separated from each sample and used for the biochemical analysis. Immediately after sacrifice, heart tissues were excised in ice cold condition. They were blotted free of blood and tissue fluids. Then they were weighed and stored at -80°C till further use for the analysis. Heart weight to body weight ratio was calculated by dividing heart weight (g) by body weight (g) and multiplying it with 100.

The activities of creatine kinase (CK), creatine kinase-MB fraction (CK-MB) and lactate dehydrogenase (LDH) in the serum were determined by commercial diagnostic kits obtained by Crest Biosystems, Coral clinical systems, Goa, India (King, 1959).

Lipid Profile

Total cholesterol (TC), high density lipoproteins (HDL) cholesterol, and triglycerides (TG) in the serum were measured by standard diagnostic kits according to the instruction given by the manufacturers (Okhawa et al., 1979; Rajadurai and Prince, 2006; Kareem et al., 2012).

Superoxide dismutase (SOD)

SOD levels in the hearts were determined by the method of McCord & Firdovich modified by Vaibhav et al. (2010). A sample (0.6 ml) was added to sodium pyrophosphate buffer (pH-8.3) followed by the addition of 0.1 ml of 186 M phenazine methosulphate, 0.3 ml of 300 mM nitro blue tetrazolium and 0.2 ml of 780 M NADH.

The reaction mixture was incubated for 90 s at 30 C and stopped the reaction by adding 1 ml of acetic acid. n-Butanol (4 ml) was then added and centrifuged at 3000g for 10 min. The absorbance of organic layer was measured at 560 nm. Data was expressed as U/mg protein.

Reduced glutathione (GSH)

GSH was estimated by the method of Elman et al. (1959). The reaction mixture contained 0.1 ml of supernatant, 2.0 ml of 0.3 M phosphate buffer (pH-8.4), 0.4 ml of double distilled water and 0.5 ml of DTNB (5,5 dithiobis-2-nitrobenzoic acid). The reaction mixture was incubated for 10 min and the absorbance was measured at 412 nm. Data was expressed as mole/g wet.wt.

Catalase activity

Catalase was estimated by the method described by Aebi and Bergmeyer, (1974). Sample was added to a 3 ml cuvette that contained 1.95 ml of 50 mM phosphate buffer (pH-7.0). Then 1 ml of 30 mM hydrogen peroxide was added and changes in absorbance were followed for 30 s at 240 nm at an interval of 15 s. Data was expressed as units per mg protein.

Myocardial thiobarbituric acid reactive substances (TBARS)

TBARS activity in the myocardium was measured by a method of Okhawa et al. (1979). Hearts were homogenized in 10% trichloro acetic acid in 4 degree C. 0.2 ml homogenate was pipetted into a test tube, followed by the addition of 0.2 ml of 8.1% sodium dodecyl sulfate (SDS), 1.5 ml of 20% acetic acid (pH-3.5) and 1.5 ml of 0.8% TBA. Tubes were boiled for 60 min at 9 degree C and then cooled in ice. Double distilled water (1.0 ml) and n-butanol:pyridine (15:1 v/v) mixture (5.0 ml) were added to the test tubes and centrifuge at 4000g for 10 min. The absorbance of developed color in organiclayer was measured at 532 nm. Data was expressed as nmole of TBARS/g wet.wt.

Electrocardiography

At the end of the experimental period, needle electrodes were inserted under the skin of the animals under light ether anesthesia in lead II position. ECG recordings were made changes in ECG pattern were considered (Sangeetha, 2009).

Histopathology

After sacrifice, the heart was rapidly dissected out and washed immediately with saline and fixed in 10% buffered formalin. The fixed tissues were embedded in paraffin and serial sections (5 μ m thick) were cut. Each section was stained with hematoxylin and eosin (H&E). The sections were examined under the light microscope for histopathological changes and photomicrographs were taken. The pathologist performing histopathological evaluation was blinded to the treatment assignment of different study groups (Vaibhav et al., 2010).

Statistical analysis

All values are expressed as mean \pm SEM for 6 animals in each group. Data for various biochemical parameters were analyzed using One-way analysis of variance. Significance was set at $p \leq 0.05$.

RESULTS AND DISCUSSIONS

The table 1 represents the effects of ISO, Losartan, Low and High Extract dose treatment on the cardiac marker enzymes including LDH and CK-MB. The activities of these enzymes were increased significantly ($P \leq 0.001$) in ISO treated rats as compared to the normal control groups rats. Extracts treated animals significantly decreased the LDH and CK-MB activities. The modulated activities of LDH and CK-MB were observed in low dose of *F.arabica*.

As a result of necrosis and leakage, the levels of diagnostic indicators of MI will increase in serum. Oral pre-treatment of FAetLD restored the activities of myocardial marker enzymes which could be due to protective effect of *F.arabica* on the myocardium, reducing the myocardial damage and thereby restricting the leakage of CK-MB and LDH.

Table 1: Effects on LDH and CKMB level in serum and heart tissue homogenate against ISO induced acute myocardial infections in rats.

Treatment	LDH activity		CK-MB activity	
	Serum (U/lt)	HTH (U/lt)	Serum (U/lt)	HTH (U/lt)
Normal control	223.53 \pm 1.8	10.27 \pm 0.60	224.3 \pm 40.45	53.60 \pm 16.51
ISO control	622.70 \pm 146.7 ^b	2.73 \pm 0.20 ^c	659.9 \pm 65.35 ^c	15.27 \pm 1.34 ^a
Losartan	254.86 \pm 30.3 ¹	10.33 \pm 0.68 ^{c2}	219.4 \pm 0.64 ³	55.98 \pm 3.98
Extract high dose	407.93 \pm 35.7 ^a	7.68 \pm 0.27 ^{cΔ}	428.8 \pm 24.02 ^{b1Y}	46.56 \pm 1.71
Extract low dose	237.06 \pm 4.7	10.23 \pm 0.20 ^c	216.5 \pm 40.88 ^{3a}	54.66 \pm 6.89

All values are mean \pm SEM, n=5, ^a $P \leq 0.05$, ^b $P \leq 0.01$, ^c $P \leq 0.001$ when compared to normal control; ¹ $P \leq 0.05$, ² $P \leq 0.01$, ³ $P \leq 0.001$ compared to ISO control, ^{Δ} $P \leq 0.05$, ^{*} $P \leq 0.01$, ^{Y} $P \leq 0.001$ compared to losartan and ^{P} $P \leq 0.05$, ^{B} $P \leq 0.01$, ^{D} $P \leq 0.001$ compared to extract low dose and extract high dose respectively.

Table 2: Effects on TG, TC & HDL levels in serum against ISO induced acute myocardial damage

Treatment	TG (mg/dl)	TC (mg/dl)	HDL (mg/dl)
Normal control	84.56±6.66	67.23±5.27	27.26±2.42
ISO control	127.40±140.95 ^a	129.97±2.96	10.50±2.98
Losartan	82.96±149.96 ^c	69.33±13.59	28.56±12.12
Extract high dose	67.66±117.60 ^{c1}	52.00±17.34	24.06±5.05
Extract low dose	82.66±39.60 ^{c3}	67.66±6.36	29.33±22.82 ^{c3yδ}

All values are mean ± SEM, n=5, ^aP≤0.05, ^bP≤0.01, ^cP≤0.001 when compared to normal control; ¹P≤0.05, ²P≤0.01, ³P≤0.001 compared to ISO control, ^ΔP≤0.05, ^{*}P≤0.01, [¥]P≤0.001 compared to losartan and ^αP≤0.05, ^βP≤0.01, ^δP≤0.001 compared to extract low dose and extract high dose respectively.

The lipid profile shows the high dose extract with increase levels of total cholesterol, triglycerides and High-density lipoprotein. The low dose extract shows the significant increase in TG but shows the decline of TC and HDL respectively compared to the Normal control with the significance value of P ≤ 0.001

Table 3: Effects on SOD, Catalase and TBARS in heart tissue homogenate against ISO induced acute myocardial damage.

Treatment	SOD (Units/mg protein)	Catalase (Units/mg protein)	TBARS (ng/mg)
Normal control	13.99±1.59	4.47±0.58	19.66±1.66
ISO control	4.34±0.15 ^c	2.14±0.00 ^c	31.3±3.42 ^b
Losartan	13.75±1.62	4.33±0.18 ^{b2}	19.16±0.33 ^{c3}
Extract high dose	10.81±1.41 ²	3.62±0.09 ^c	15.33±0.33 ^{3*}
Extract low dose	13.57±0.46	4.93±0.07 ^{c1}	19±0.76 ^{3*}

All values are mean ± SEM, n=5, ^aP≤0.05, ^bP≤0.01, ^cP≤0.001 when compared to normal control; ¹P≤0.05, ²P≤0.01, ³P≤0.001 compared to ISO control, ^ΔP≤0.05, ^{*}P≤0.01, [¥]P≤0.001 compared to losartan and ^αP≤0.05, ^βP≤0.01, ^δP≤0.001 compared to extract low dose and extract high dose respectively.

The high dose extract induced rats showed the significant (P≤0.05) decrease in the activities of SOD, Catalase and Thiobarbituric acid reactive substances as compared to the normal control rats. As shown in the table 3 represents the increase in the antioxidant compared to ISO control. The SOD analysis of ISO induced MI was showed less activity when compared to normal control rats. The activity of SOD activity was brought near normal in *F.arabica* extract groups. Catalase activity was decreased in ISO induced MI rats, this was brought near normal in *F.arabica* extract groups. The thiobarbituric acid reactive substances exhibits increased in ISO induced MI rats and this was brought near normal in *F.arabica* extract groups.

The overall low dose extract shows the less value compared to the high dose extract as show in the table 3. Oxidative stress was evidenced by the generation of free radical which might be scavenged by augmentation of endogenous antioxidants in the myocardium after pharmacological intrusion. Administration of ISO induced the oxidative stress and the morphological changes associated. The protective role of extract may be due to myocardial adaptation and enhancement of myocardial endogenous antioxidants.

Table 4- Effects of different doses of extract and Losartan on electrocardiographic parameters in ISO induced MI

Treatment	Heart rate	QRS duration (ms)	QT segment (ms)	RR interval (ms)	PR interval (ms)
Normal control	206.6±17.3	53.6±2.3	72.6±5.4	214.6±4.3	70.6±0.6
ISO control	394.6±15.6 ^c	38±1.1 ^a	83.3±1.6	160±11.5 ^c	82.6±1.4
Losartan	245±2.8 ³	63±2.0 ²	123.3±8.8 ^{b1}	252±1.1 ^{a3}	57.3±1.7 ²
Extract high dose	253.3±7.2 ³	100±5.7 ^{c3y}	134.6±2.9 ^{c2}	235.6±3.4 ³	111.3±6.9 ^{c2y}
Extract low dose	241.6±1.6 ³	62±1.1 ^{2δ}	123.3±8.8 ^{b1}	252±1.3 ^{a3}	57.3±1.7 ^{2δ}

All values are mean ± SEM, n=5, ^aP≤0.05, ^bP≤0.01, ^cP≤0.001 when compared to normal control; ¹P≤0.05, ²P≤0.01, ³P≤0.001 compared to ISO control, ^ΔP≤0.05, ^{*}P≤0.01, [¥]P≤0.001 compared to losartan and ^αP≤0.05, ^βP≤0.01, ^δP≤0.001 compared to extract low dose and extract high dose respectively

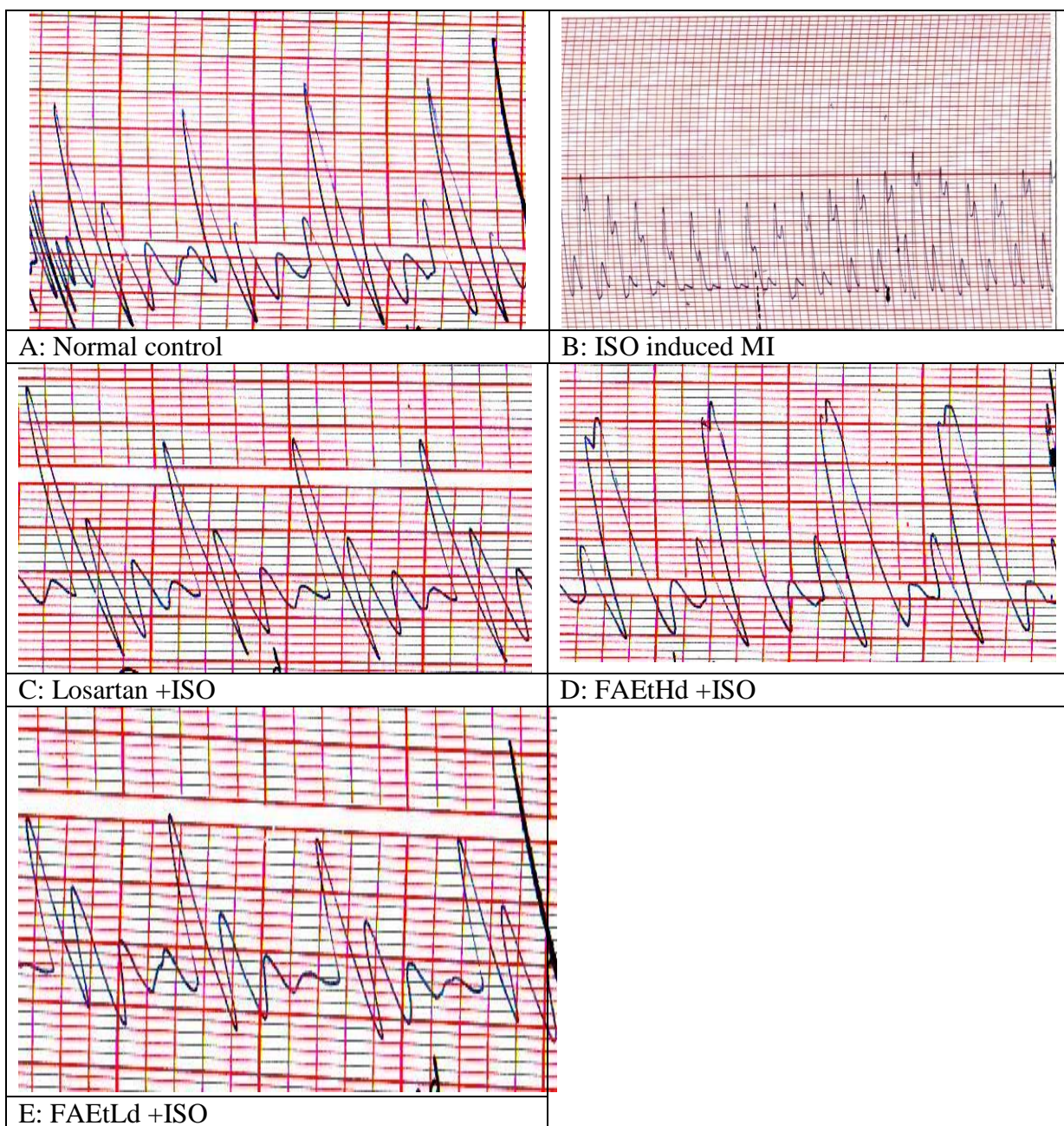


Fig. 1: Histopathological studies of heart tissues of control and experimental rats

Electrocardiographic pattern of normal and experimental animals is shown in Fig. 1 A-E and table 4. Normal control and *F.arabica* treated rats showed normal pattern of ECG, whereas rats treated with ISO showed a significantly ($P \leq 0.01$) increase in ST-segment and significantly ($P \leq 0.01$) decrease in R-amplitude as compared to control rats, indicative of infarcted myocardium. ISO treated rats also exhibited the pathological Q wave, indicating the induction of transmural myocardial infarction. Moreover, a significantly ($P \leq 0.01$) for P wave and R-R interval and $P \leq 0.001$ for QRS complex decrease in P wave, QRS complex, R-R interval and a significantly ($P \leq 0.001$) increase in heart rate was observed in rats injected with ISO as compared to control rats. Treated rats showed significant ($P \leq 0.05$) decrease in ST-segment and increase in R-amplitude as compared to ISO alone treated rats. Extracts treated also resulted in a significantly increase ($P \leq 0.01$ for QRS complex and $P \leq 0.05$ for R-R interval) in QRS complex and R-R interval along with a significantly ($P \leq 0.05$) decreased heart rate when compared to ISO rats.

Histopathology

As shown in the figure 6 A-E, illustrates the histopathological photographs of heart tissues of control and experimental rats. Histopathological examination of myocardial tissue obtained from normal control animals exhibited clear integrity of myocardial membrane. Normal untreated rats showed normal cardiac fibers without any infarction and infiltration of inflammatory cells was not seen in this group.

Histopathological findings confirmed the induction of MI by ISO. Heart tissues from ISO treated rats showed widespread myocardial structure disorder as compared to control group. Pretreatment with *F.arabica* extracts depicted decreased degree infiltration of inflammatory cells and the morphology of cardiac muscle fibers. High and low dose extract rats showed no change in histo architecture of heart tissue as compared to normal control heart tissues.

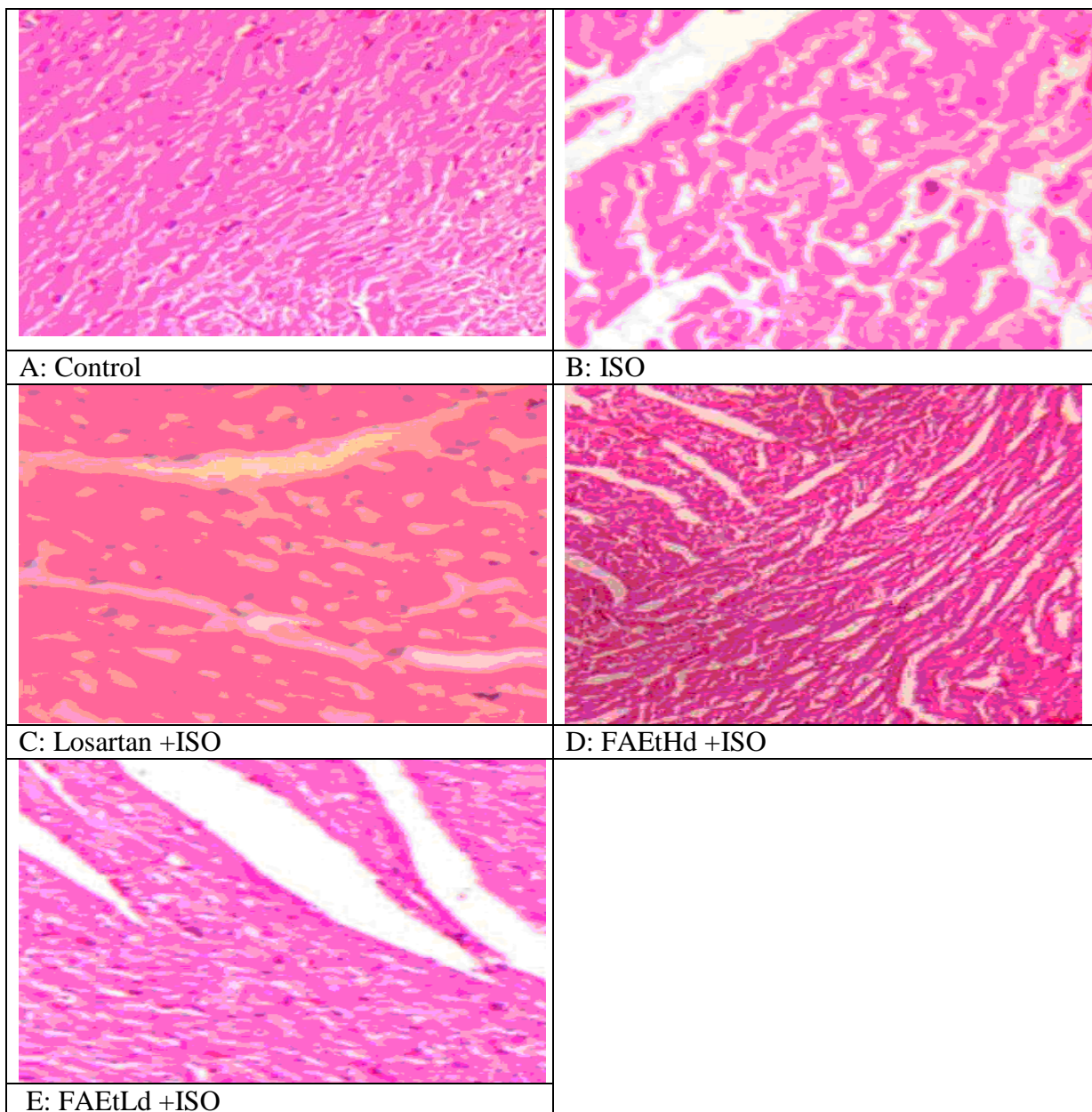


Fig. 2: Histopathological studies of heart tissues of control and experimental rats

CONCLUSION

In conclusion, present study demonstrated that subcutaneous injections of ISO produced myocardial infarction in rats as evident by the release of myocyte injury markers in serum. Myocardial lesions were associated with decreased antioxidant defence status in the heart electrocardiographic, histopathological changes and release of inflammatory markers. In addition, the present study provided experimental evidence that extracts maintained the antioxidant enzyme levels and improved cardiac performance following ISO administration. This finding might be a scientific support to understand the beneficial effects of *F.arabica* against myocardial injury, in which oxidative stress has long been known to contribute to the pathogenesis. For the first time toxicity studies have shown that *F.arabica* is safe at 2g/kg bw and 5g/kg bw at low and high dosage respectively.

REFERENCES

- Aebi H, Bergmeyer HU. (1974). Methods of Enzymatic Analysis. 2nd ed. vol. 2. Chemic Academic Press Inc., Verlag ;673-685.
- Ageely, Hussein M, Suneetkumar Gupta, and Bhagyashree R Patil. (2014). "Review of Ethnomedicinal Plant *Fagonia*." 5: 22–28.
- Ellman GL. (1959). Tissue sulphhydryl groups. Arch Biochem Biophys. 82: 70- 77.
- Fahn Abraham, and Carmela Shimony. (1996). "Glandular trichomes of *Fagonia* L.(Zygophyllaceae) species: structure, development and secreted materials." Annals of Botany 77, no. 1: 25-34.
- Hamid K , Kabir MS, Ullah MO, Bulbil IJ, Siddiqua M, Choudhary MS. (2010). Effect of Ardhabilva Kvatha Curna, an ayurvedic formulati on, on liver and kidney function parameters of rat plasma after chronic administration. Biol Med.;2:49-57.
- Kareem, Mohammed Abdul, Saayi Krushna Gadhamsetty, Althaf Hussain Shaik, E. Maruthi Prasad, and Lakshmi Devi Kodidhela. (2013). "Protective effect of nutmeg aqueous extract against experimentally-induced hepatotoxicity and oxidative stress in rats." Journal of Ayurveda and integrative medicine 4, no. 4: 216.
- King J. (1959). A routine method for the estimation of lactic dehydrogenase activity.J Med Lab Tech.;16:265e272.
- Krushna, G. S., M. A. Kareem, V. D. Reddy, P. Padmavathi, and S. A. Hussain. (2012). "Aegle marmelos fruit extract attenuates ISO-induced oxidative stress in rats." Journal of clinical biochemistry and nutrition 50, no. 3: 199-204.
- Maruthi Prasad E., Nandakumar Y., Lakshmi Devi K. (2015). Molecular Docking Studies of Phytochemicals of *Vitex Negundo* (L.) Against Adenosine A1 Receptor as Therapeutic Target In Cardiovascular Diseases. J Bioinfo Proteomics Rev 1(2): 1- 5.
- Meena AK, Rao MM . (2010). Folk herbal medicines used by the Meena community in Rajasthan. Asian J. Tradit. Med.;1:19-31.
- Mosca, Lori, JoAnn E. Manson, Susan E. Sutherland, Robert D. Langer, Teri Manolio, and Elizabeth Barrett-Connor. (1997). "Cardiovascular Disease in Women A Statement for Healthcare Professionals From the American Heart Association." Circulation 96, no. 7: 2468-2482.
- Okhawa H, Oohishi N, Yagi K. (1979). Assay for lipid peroxides in animal tissues by thiobarbituric acid reaction. Ann Bichem.;95:351-358.
- Patel YS, Joshi EP, Joshi PN. (2010). Ethnobotanical Study of Tapkeshwari Hill, Bhuj, Kachchh, India. Life sci. Leaf.; 2:22–31.
- Pfeffer, JANICE M., Marc A. Pfeffer, PETER J. Fletcher, and E. Braunwald. (1991). "Progressive ventricular remodeling in rat with myocardial infarction." American Journal of Physiology-Heart and Circulatory Physiology 260, no. 5: H1406-H1414.
- Raghavendra, H. L., Vijayananda, B. N., Madhumathi, G. H., and Vadlapudi, K. (2010). In vitro antioxidant activity of *Vitex negundo* L. leaf extracts. Chiang Mai Journal of Sciences, 37(3), 489-497.
- Rahmathulla, SB Mahammad, E. Maruthi Prasad, K. Bheemewsaraiah, and S. Manjunatha. (2012). "Effect of *Tribulus terrestris* (L.) on liver in ISO-induced myocardial infarction." International Journal of Research in Biochemistry and Biophysics 2, no. 4: 10-12.
- Rajadurai, M., Prince, P.S.M., (2006). Preventive effect of naringin on lipid peroxides and antioxidants in ISO-induced cardiotoxicity in Wistar rats: biochemical and histopathological evidences. Toxicology 228, 259–268.
- Ribeiro, D.A., Buttros, J.B., Oshima, C.T.F., Bergamaschi, C.T., Campos, R.R., (2009). Ascorbic acid prevents acute myocardial infarction induced by ISO in rats: role of inducible nitric oxide synthase production. J. Mol. Hist. 40, 99–105.
- Sangeetha T, Darlin SQ. (2009). Preventive effects of S-allyl cysteine sulphoxide (Alliin) on mitochondrial dysfunction in normal and ISO induced cardiotoxicity in male Wistar rats: a histopathological study. Mol Cell Biochem.; 32:1e8.

- Shaik, Althaf Hussain, S. N. Rasool, A. Vikram Kumar Reddy, M. Abdul Kareem, G. Saayi Krushna, and K. Lakshmi Devi. (2012). "Cardioprotective effect of HPLC standardized ethanolic extract of *Terminalia pallida* fruits against ISO-induced myocardial infarction in albino rats." *Journal of ethnopharmacology* 141, no. 1: 33-40.
- Vaibhav Patel, Aman Upaganlawar, Rishit Zalawadia, R. Balaraman, (2010). Cardioprotective effect of melatonin against ISO induced myocardial infarction in rats: A biochemical, electrocardiographic and histoarchitectural evaluation, *European Journal of Pharmacology*, 644, 160–168.

ISSN : 0976-4550

INTERNATIONAL JOURNAL OF APPLIED BIOLOGY AND PHARMACEUTICAL TECHNOLOGY



Email : editor.ijabpt@gmail.com

Website: www.ijabpt.com