


STUDY OF ACUTE TOXICITY OF INORGANIC FERTILIZER NPK (15:15:15) ON CAT
FISH, *HETEROPNEUSTES FOSSILIS*Ganesh Kumar Maurya¹, Chandan Malick¹, Ritwik Mondal¹ and Lokesh Gambhir^{2*}¹Dept. of Zoology, Banaras Hindu University, Varanasi, India-221005²Department of Life Science, Shri Guru Ram Rai Institute of Technology and Sciences (SGRRITS), Dehradun, Uttarakhand, India-248001.

ABSTRACT: Acute toxicity of commonly used inorganic fertilizer NPK (15:15:15) to cat fish (*Heteropneustes fossilis*) was evaluated under semistatic conditions using behavioural, biochemical and histopathological parameters. Two different sub-lethal doses of NPK (0.075 g/l as low dose and 0.1 g/l as high dose) were taken with respect to control for the present study. Fish has shown increased surface activity and ventilation rate in response to both doses of NPK. In biochemical studies, the levels of muscle protein, lipid and glycogen as well as liver lipid content was observed to decrease with increase in dose of NPK. On the other hand, serum glucose and cholesterol were found to be increasing with increase in dose of NPK. The levels of stress signalling molecule like nitric oxide increased with increase of dose of toxicant to fish. The level of electrolytes has shown biphasic response with significant increase in Ca²⁺ and radical decrease of K⁺ at low dose however, at high dose such intense fluctuation were not observed. In histopathological study, the experimental air breathing organ showed proliferating mucous cells, sloughing of vascular epithelium, disorganization of respiratory material and dilation of blood capillary. Hyperplasia of mucous cell and sloughing of club cells in skin was reported for low dose exposure. Liver histology exhibited nuclear pycnosis, necrosis, narrowing of sinusoids and fatty degeneration around hepatic cord. In gills, hyperplasia of mucous cells, excessive mucous secretion and exfoliation of epithelial cells in the lining of secondary lamellae was observed at both low and high dose. Kidney histology exhibited epithelial cell shrinkage of renal tubules at both low dose & high dose of NPK. Present study provides a detailed insight of the perturbation of cellular responses in fishes to exogenous NPK fertilizer. It further provides an understanding of the impact of employing chemical fertilizers on aquatic fauna.

Key words: Biochemical analysis, Chemical fertilizers, *Heteropneustes fossilis*

*Corresponding author: Lokesh Gambhir, Department of Life Sciences, Shri Guru Ram Rai Institute of Technology and Sciences, Dehradun, Uttarakhand, India E-mail: gambhir.lokesh@gmail.com

Tel: +918755487416

Copyright: ©2016 Lokesh Gambhir. This is an open-access article distributed under the terms of the Creative Commons Attribution License , which permits unrestricted use, distribution, and reproduction in any medium, provided the original author and source are credited

INTRODUCTION

Freshwater is the source of virtually all drinking water, which constitutes less than three percent of total water content of earth. During the past few decades, magnitude of pollutants released into the aquatic environment have augmented due to increase in population, industrialization, increase in the production and consumption of plethora of new synthetic fertilizers. Fresh water ecosystem is under susceptible existence due to direct or indirect contaminations by effluents from industries, domestic and agricultural run-off that accounts a major environmental concern. High concentration of pollutants in fresh water causes progressive flagging of flora and fauna. It is also among the potent factors causing transmission of spectrum of diseases in humans. The pollutants act as a stressor to aquatic life and organisms retort to it by developing necessary potential to counteract the induced stress.

The mode of action of toxicants of poisoned aquatic life is better understood by monitoring biochemical and histological changes beside mortality studies. Fish and other aquatic animals are subject to a broad variety of stressors because their homeostatic mechanisms are highly dependent on prevailing conditions in their immediate surroundings. The biochemical and histological changes occurring in the body could serve as potent indicators of stress.

NPK, (Nitrogen: phosphorous: potassium), an inorganic fertilizer, is most widely used in agriculture as an economical, balanced and effective fertilizer. Its efficacy in promoting growth of plants and increasing production is uncontested. However, in animals it is responsible for the manifestation of multiple disorders ranging from inhibition of growth to mortality. Its use as a fertilizer has been shown to diminish fish production and induce mortality in aquaculture (Jhingran, 1982). Employing different fertilizers in fish ponds indicated a negative correlation between fish production and levels of organic nitrogen (Meehan and Marzulli, 1945). NPK is also known to bring about pernicious physiological changes in fish, *Heteropneustes fossilis* (Sriwastawa and Shistava 1977, Narain and Sriwastawa 1979, Srivastava and Narain 1982). Although known for its harmful effects, the interaction of NPK fertilizer with fishes and other commercially important animals inhabiting the water masses which are vulnerable to large scale contamination with this nitrogenous product has received little attention.

H. fossilis is an omnivorous and oviparous teleost. This catfish is distributed throughout the Asian continent in fresh and brackish water ecosystems include marshy, and derelicts ponds having low level of water and dissolve oxygen content. It breeds in confined water during the monsoon months. It is an important edible fish with great nutritional and medicinal value. Under stress condition, energy requirement increases to maintain homeostasis of body, to fulfil the need, glucose level in serum increases by catabolism of stored food reserves. Increased serum glucose level in response to other toxicant was earlier reported by other workers (Shobha, k. *et al.*, 2007, Bedii and Kenan, 2005, Chowdhury MJ, *et al.*, 2004). Present study was undertaken to monitor the response of fishes to exogenous NPK fertilizer. Multiple parameters were examined including behavioural changes, biochemical changes, osmoregulation and histological changes which helps in providing the insight to the generated response.

MATERIALS AND METHODS

Chemicals

Godavari Nutri+ water soluble NPK fertilizer of ratio 19:19:19, manufactured by Coromandel Fertilizers limited, Andhra Pradesh, India was purchased from local fertilizer shop. All the other chemicals used for biochemical estimation and histology were purchased from Sigma-Aldrich, Co., USA. GOD-POD End Point Assay kit AUTOPAN and CHOD-PAP End Point Assay kit liquid GOLD manufactured by Span Diagnostic Ltd. was used for measurement of serum glucose and cholesterol respectively. While SODIUM - POTASSIUM KIT, Pariksha Neochem Pvt. Ltd. was used for serum electrolyte measurement.

Collection of fish

The air-breathing catfish, *H. fossilis* was selected for the study because this fish is very hardy due to their bi-modal respiratory mechanism; hence can easily be maintained in laboratory conditions. *H. fossilis* residing near the top of the food chain is a valuable bio-indicator of the overall system analysing health; hence detecting any change or damage in the fish health may easily be illustrated to the public. *H. fossilis* (42 ± 7 g, 18 ± 2 cm) were purchased from commercial fisherman from the chaukaghat, Varanasi, India and acclimatized under laboratory condition in three separate plastic tubs for 2 weeks using approximately 30 litres of dechlorinated and well oxygenated tap water at pH 7.0 and temperature $24 \pm 1^\circ\text{C}$. The fishes were fed with chopped goat liver on alternate day. Holding tubs were cleaned daily and water was changed every 24hours to discard faecal material and left over food.

Selection of fertilizer dose

The acute toxicity test design was conducted as described previously (Altinok *et al.* 2006). Briefly, after acclimation, two different sub lethal concentration and control of NPK (19:19:19) fertilizers (OMOREGIE E, *et al.*, 2004, Capkin E, *et al.*, 2010, Uhuo Cosmas A, *et al.*, 2013) were prepared and introduced into low dose: 0.075g/lit. ; high dose: 0.1g/lit. and control: 0.0g/lit. This study was conducted under OECD Guideline No. 203 for static-renewal test conditions (OECD, 1992). Each experimental tub was stocked with 20 fishes and control stocked with 15 fishes. Concentrations of fertilizers were re-established to maintain the original levels while fifty percent of the test solution was renewed each day. The exposures of NPK fertilization were given for 15 days.

Tissue and serum collection

Fishes were sacrificed after 15 days of exposure. Blood was collected from post caudal vein and serum was extracted after centrifugation and stored in -20°C . Liver and muscles (without skin) were quickly extirpated, washed with 0.6 % saline weighted, blotted and kept frozen at -20°C for further biochemical analysis. Similarly, kidney, gills, air breathing organs (ABO) and skin were also preserved in aqueous Bouines solution for histological study.

Behavioural studies of fish in response to NPK

The surface activity (SA) and ventilation rate (VR) were monitored to study the effect of NPK on behaviour of fish. The surface activity was noted each time the fish comes to water surface to gulp air and ventilation rate was noted by observing the number of times the fish ventilate by opening and closing operculum chamber. Both of the parameters were noted for each minute, continuing up to 5 min followed by 10 min interval. This was repeated thrice for three individual fishes for low dose: 0.075g/lit. ; high dose: 0.1g/lit. and control: 0.0g/lit. The changes in skin texture and body colour of catfish were observed.

Biochemical assessment of different biomolecules in response to NPK

Protein estimation in muscles

Total protein content in muscle was estimated calorimetrically by Lowry's method (Lowry *et al.*, 1951). Briefly, 100 mg of muscle tissue was homogenised in 0.9 ml of 10% T.C.A. and centrifuged at 5000 rpm for 20 minutes. Pellet was dissolved in 1ml of 0.1 N NaOH, heated at 90°C for 10 min and again centrifuged at 4000 rpm for 10 minutes. Supernatant obtained was used for protein estimation. To the test samples alkaline copper sulphate reagent was added (1:3) in each tube. Incubated for 10 minutes at room temperature and 150µl Folin-Ciocalteau reagent was added and incubated further for 45 minutes in dark and O.D. was taken at 660 nm. The values were calculated against Bovine Serum Albumin (BSA) used as standard and were represented as µg/mg of tissue weight.

Lipid estimation

Total Lipid in liver and muscle was measured as described previously (Folch *et al.*, 1957). In brief, 200 mg of muscle while 100 mg of liver were homogenized in chloroform and methanol (2:1, v/v) in potter Elvehjem glass homogenizer fitted with Teflon pestle. Suspension was filtered and residues were resuspended in chloroform : methanol solution and reprocessed as above. Pooled filtrate was kept in dark for 2h and then mixed thoroughly with equal volume of 0.6 % NaCl in separating funnel and kept in dark for overnight at room temperature. Lower organic phase was collected in glass vial, dried, kept for 24h at room temperature and weighed.

Glycogen estimation

Total glycogen in muscle was measured by calorimetric method as described earlier (Carroll *et al.*, 1956). Briefly, 200 mg muscle cells were digested in 2 ml of 30 % KOH in water bath at 90°C for 10 minutes. The digested sample was cooled overnight at 4°C, precipitated with 95 % ethanol and centrifuged for 15 min at 10000 rpm. This step was repeated twice. Finally the residues containing glycogen were dissolved in 1ml of distilled water and measured using 2 ml of 0.2 % Anthrone reagent (made in conc. H₂SO₄) at 620 nm. The values were calculated against D-glucose used as standard and were represented as µg/mg of tissue weight.

Total serum glucose and serum cholesterol determination

Rapid enzymatic determination of total serum glucose and serum cholesterol was done following manufacturer's protocol using GOD-POD End Point Assay kit and Kinetic Assay (Trinder, P *et al.*, 1969) and CHOD-PAP method (Roeschlau, P *et al.*, 1974) respectively.

Estimation of serum NO

Biochemical estimation of serum NO was done by Nitric oxide (NO²/NO³) Assay. Standard was prepared by taking different concentration of 10 mM KHNO₃. Briefly, 100 µl of plasma was collected from each sample and 400 µl of carbonate buffer along with 100-150 µg of activated Cu-Cd alloy was added. From it 100 µl of the solution was taken in duplicate and were incubated at 37°C for 2 hours. After incubation, 400 µl of freshly prepared 0.35 N NaOH was added followed by addition of 100 µl of freshly prepared ZnSO₄ in each tube. The tubes were vortexed and further incubated at 37°C for 10-15 minutes. The tubes were centrifuged at 5000 rpm for 15-20 minutes. The supernatant was collected from each tube and 50µl NEDD and 50µl sulphonilemide were added. O.D. was taken at 540 nm and concentration of serum NO was calculated in µg/ml of serum with respect to standard.

Serum electrolyte estimation:

The colorimetric assay was done for four major serum electrolytes viz. sodium, potassium (Teitz, 1994), calcium and chloride in serum using commercially available assay kit (SODIUM - POTASSIUM KIT, PARIKSHA NEOCHEM Pvt. Ltd.) for each electrolyte following manufacturer's protocol.

Histological studies in response to sub-lethal doses of NPK

Histopathological study was done using Heamatoxylin-eosin staining method after paraffin embedded sectioning of tissues. Briefly, Different vital organs including gills, ABO, liver, kidney and skin were extirpated on day 15, chopped into small pieces and fixed with aq. Bouin's fluid for 24 hrs. Fixed tissue was processed by progressive dehydration of tissues in ethanol, clearing in xylene, paraffin vacuum infiltration, and embedded in to paraffin blocks. The sections of 5µm thickness were cut using a rotary microtome (AO 820, USA). The sections of tissues were stained in eosin and Harris haematoxylin and examined using upright trinocular light microscope (Nikon) attached to CCD camera.

Statistical Analysis

The statistical analysis was done using analysis of variance with Microcal OriginPro 8.0 software followed by post hoc analysis using Schiffe's test. *refers to $p < 0.01$, as compared to control, #refers to $p < 0.05$ as compared to control group. Data points represent mean \pm SEM from three replicates, and two independent experiments were performed.

RESULTS

Sub-lethal doses of NPK induced modulation in behaviour of fish

Two sub-lethal doses of NPK (15:15:15) viz. 0.075g/l and 0.1 g/l were tested for behavioural study like surface activity (SA) and ventilation rate (VR). There was no mortality in fishes during the acclimation period before fertilizers treatment. Toxicity tests yielded no mortality in control group. Interestingly, it was observed that both the doses changed normal behaviour of fish with respect to control fish. Fishes exposed to low dose of NPK fertilizer and high dose of NPK fertilizer had a rapid respiration rate, loss of equilibrium, erratic swimming, flashing and crowding at the water surface. After long periods of motionlessness, it was seen that the fish lied down at the bottom of water tub with sudden onset of motion. A significant increase in VR as well as SA at low dose as well as high dose of NPK fertilizer was observed as compared to control group (Fig. 1).

Both low and high doses of NPK modulated the levels of protein, lipid and glycogen in muscle and liver of *H. fossilis*.

In response to different doses of NPK, stress was monitored by measuring the level of different biomolecules. The protein content of fish muscle was observed to reduce significantly in response to both sub-lethal doses of NPK with respect to the control untreated fish population (Shobha, K. *et al.*, 2007) (Fig. 2A). Similarly, lipid content was also measured for liver and muscle in response to both low and high doses of NPK. It was found that lipid content of both the tissues have reduced significantly with respect to control fish population (Fig. 2C and D), suggesting the altered physiology of fish to combat stress generated by exposure to NPK. Intriguingly, muscle glycogen level was found to reduce significantly at high dose with respect to control (Fig. 2B). These observations are in correlation with earlier findings by other workers (Shobha, k. *et al.*, 2007, Bedii and Kenan, 2005). A decrease in the muscle glycogen level clearly indicates its rapid utilization to meet the enhanced energy requirement in fish exposed to NPK through glycolysis or Hexose Monophosphate Pathway.

Exposure to NPK induced hyperglycemia and hypercholesterolemia in fishes:

Serum glucose and cholesterol levels were measured calorimetrically in response to both sub-lethal doses of NPK. Interestingly, the level of glucose and cholesterol in serum was found to be significantly higher for both sub-lethal doses of NPK compared to control (Fig. 3). Increase in serum glucose levels in response to toxicant like cadmium was earlier reported by other workers (Shobha, K. *et al.*, 2007, Bedii and Kenan, 2005, Chowdhury MJ, *et al.*, 2004).

Exposure to NPK induced an increase in NO levels and altered levels of electrolyte:

Nitric oxide (NO) is a known signaling messenger that plays a pivotal role in maintaining cell physiology. Interestingly, treatment with high dose resulted in elevated levels of NO in plasma; however at low dose the levels were comparable to control contemplating the relevance of NO in stress response signaling at high doses (Fig. 4A). Further, the electrolyte concentration was observed to have biphasic response with significant increase in Ca^{2+} & major decrease of K^+ at low dose, however at high dose levels were comparable with control (Fig. 4C). There was no change in levels of Cl^- , however a minor increase in Na^+ in both low & high dose was observed as compare to control (Fig. 4B). This indicates physiological modulation in level of different electrolytes in response to stress.

NPK treatment altered the histology of air breathing organ (ABO), skin, kidney, gill and liver of *H. fossilis*.

In the ABO major histological changes were seen in mucous cells. Mucous cell showed proliferating potential at low dose whereas sloughing of vascular epithelium was seen at high dose. Disorganization of respiratory material and dilation of blood capillary were seen in both doses (Fig. 5A). Further, changes in histology of skin were observed at low dose in mucous cell and club cell. Hyperplasia of mucous cell and sloughing of club cells of skin occurred at low dose of NPK (Fig. 5B). Exfoliation of epithelial cell lining and disorganization of epithelial cell layer was also seen. Liver is a centre for metabolism, detoxification of xenobiotic and excretion of harmful substances. Exposure to high dose of NPK resulted in larger lesions including nuclear pycnosis, necrosis, narrowing of sinusoids, congestion and vascular degeneration (Fig. 5C).

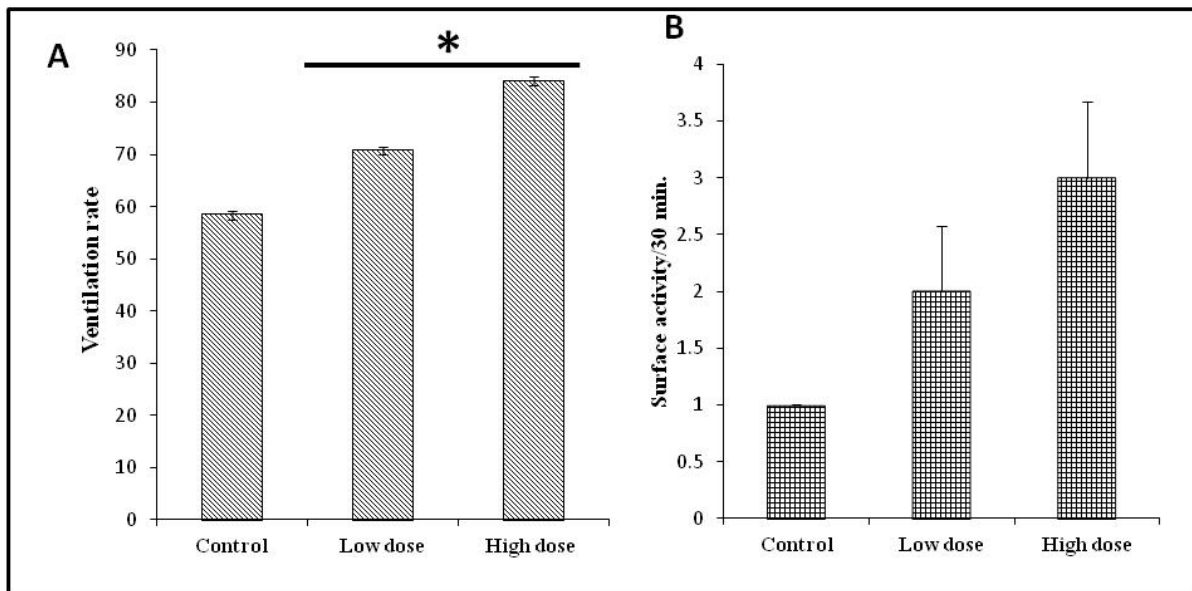


Figure 1. Behavioral changes in *H. fossilis* in response to NPK. (A) Ventilation rate (B) surface activity/30 minutes.

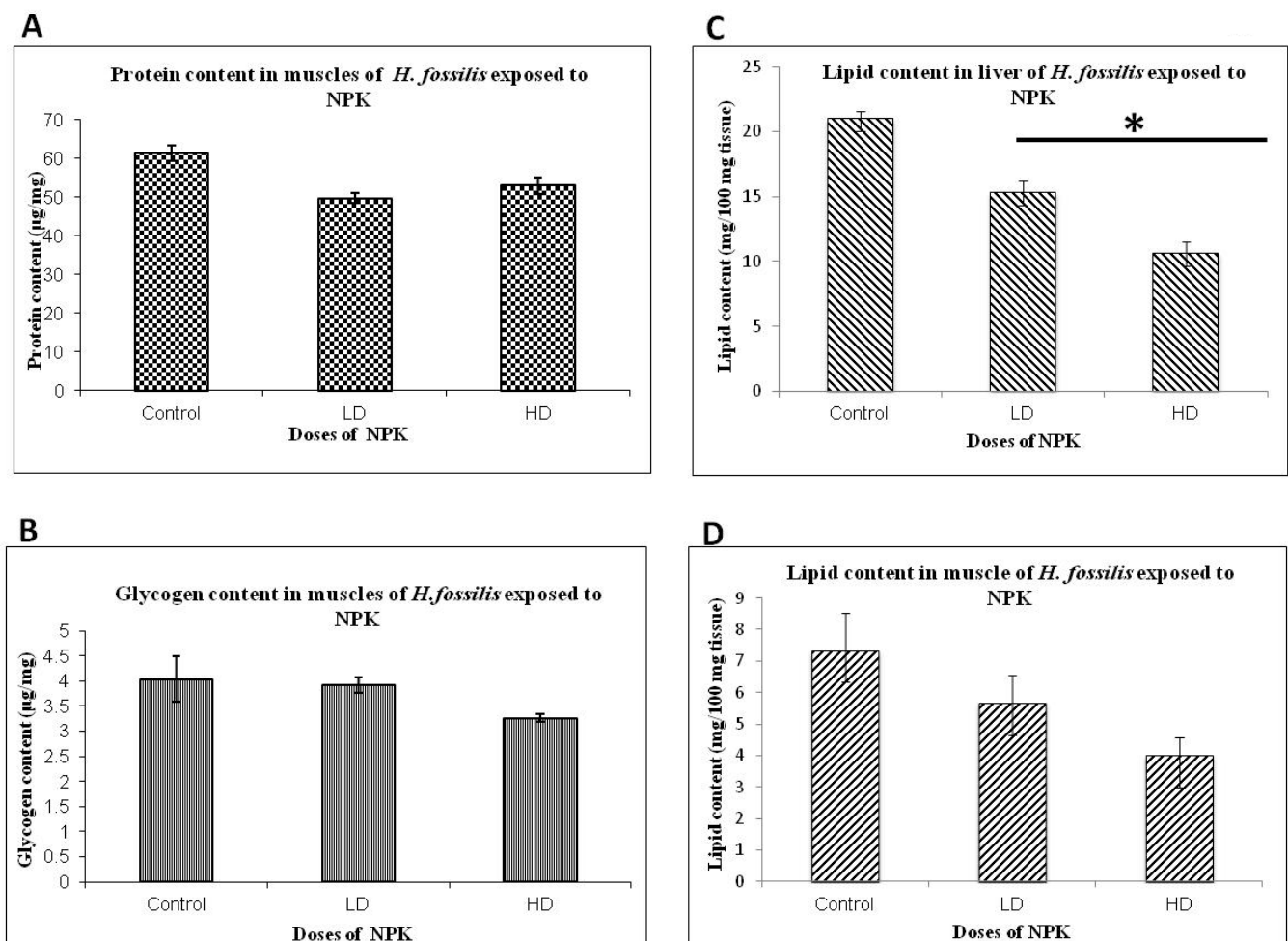


Figure 2. Biochemical estimation of different biomolecule in *H. fossilis* exposed to NPK. (A & B) protein and glycogen content (µg/mg) in fish muscle respectively. (C & D) lipid content in liver and muscle respectively of *H. fossilis*

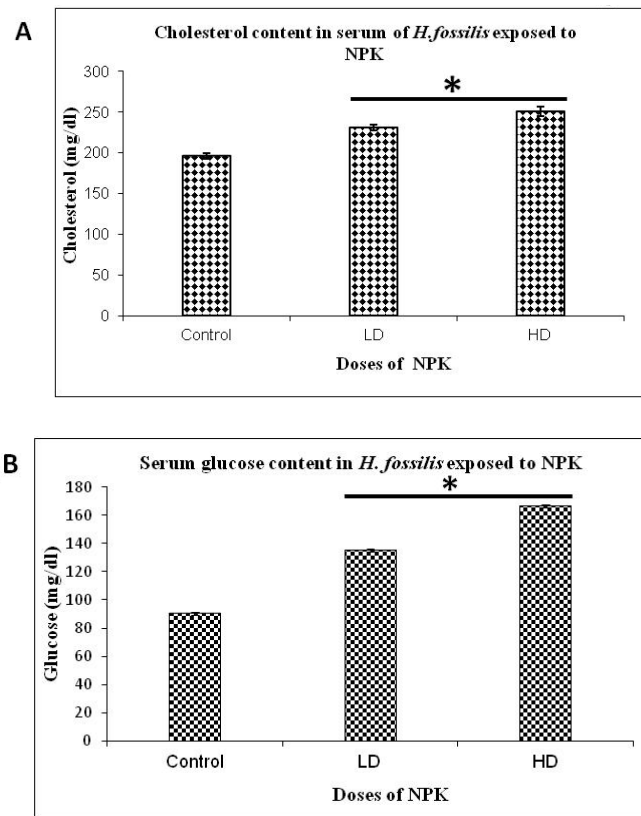


Figure 3. Biochemical estimation of different biomolecule in *H. fossilis* exposed to NPK. (A) Serum cholesterol content (mg/dl) (B) Serum glucose content (mg/dl)

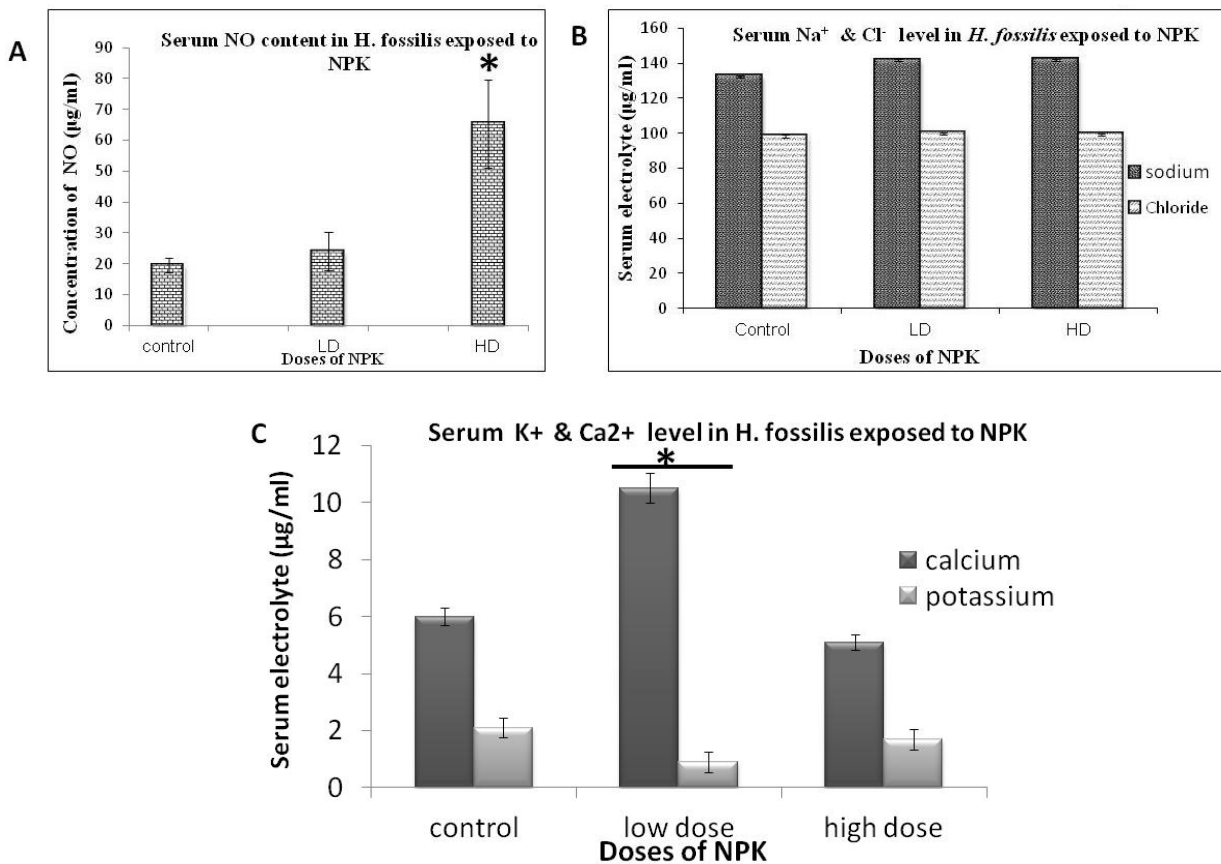


Figure 4. (A) Serum nitric oxide (NO) level in *H. fossilis* exposed to different doses of NPK. Estimation of serum electrolytes in *H. fossilis* exposed to different doses of NPK. (B) Serum sodium and chloride level (µg/ml). (C) Serum potassium and calcium level (µg/ml).

Fig. 5

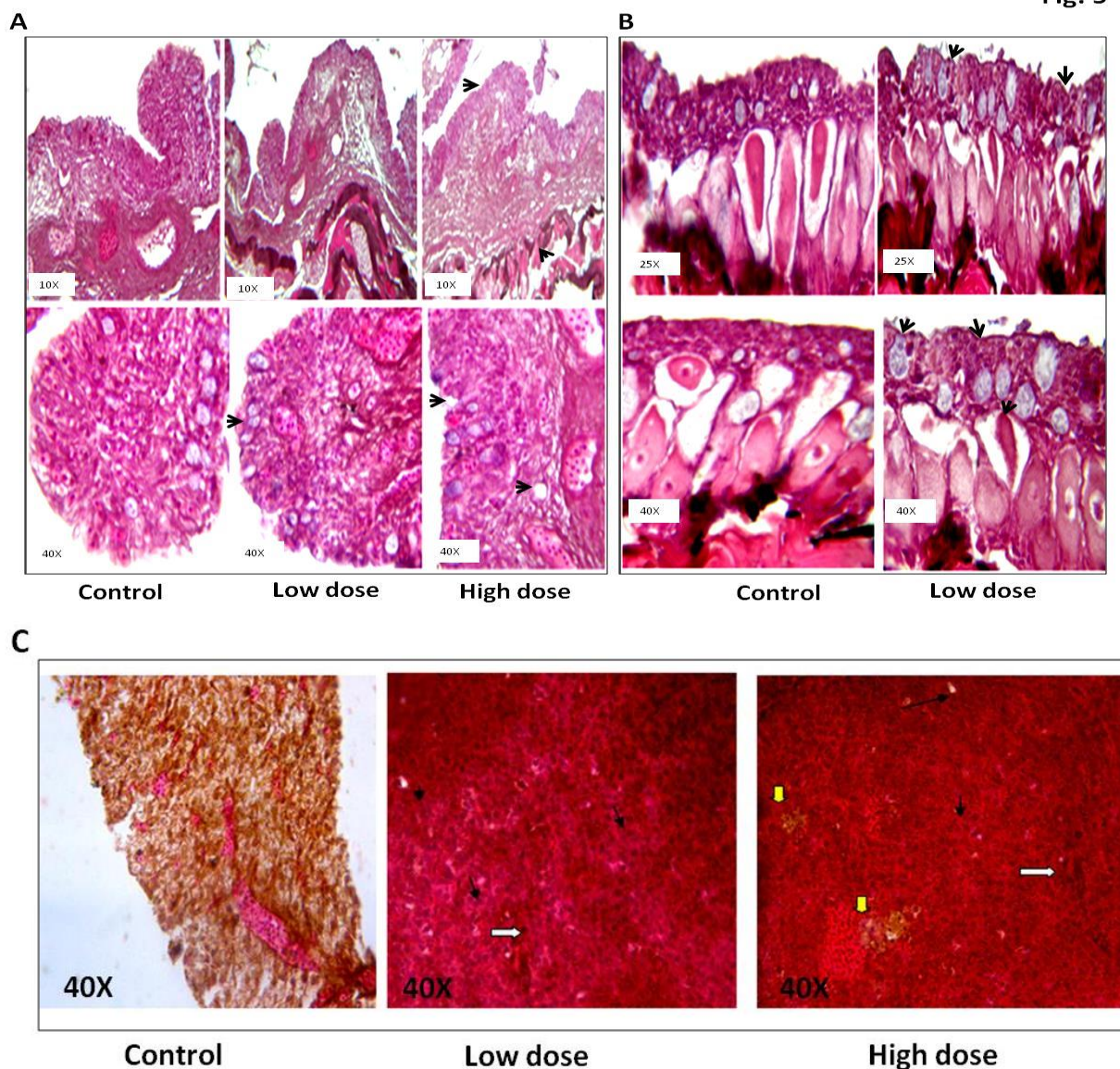


Figure 5. Histopathology studies (A) Air breathing organ (ABO) of *H. fossilis* in response to different doses of NPK. In comparison to control, ABO of low dose is showing mucous cell proliferation and sloughing of vascular epithelium. ABO exposed to high dose exhibited extensive mucous cell proliferation, disorganization of respiratory material and dilation of blood capillary. (B) Histopathology of skin epidermis in response to low dose of NPK showed hyperplasia of mucous cell, sloughing of club cells and exfoliation of epithelial cell lining and disorganization of epithelial cell layer. (C) Histopathology of liver in response to different doses of NPK in *H. fossilis*. In comparison to control, low and high doses of NPK alter liver tissue organization and resulted in nuclear pycnosis (white arrow) fatty degeneration (yellow arrow) necrosis & vacuolar degeneration (black arrow) in liver.

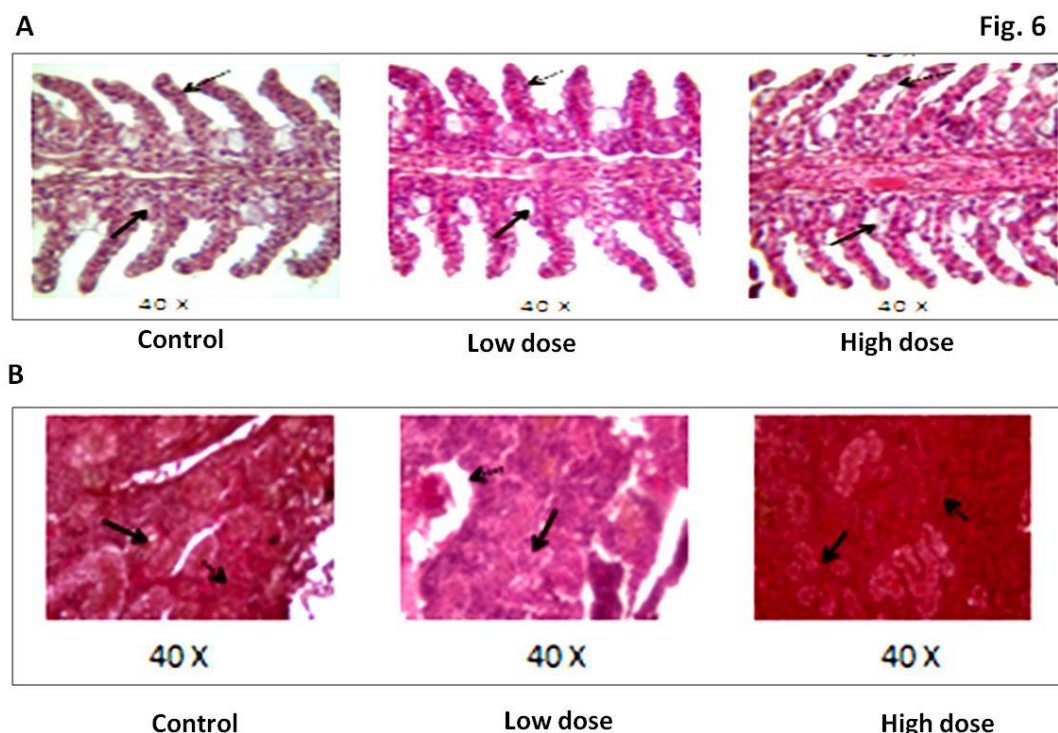


Figure 6. (A) Histopathology of gills in *H. fossilis* in response to different doses of NPK. Thick arrows indicate hyperplasia of mucous cells at both low and high dose compare to control. Excessive mucous secretion was observed at low dose & high dose gills. Thin arrows indicate exfoliation of epithelial cells in the lining of secondary lamellae in both low and high dose in comparison to control. (B) Histopathology of kidney in response to different doses of NPK on *H. fossilis*. Thick arrows indicate epithelial cells of renal tubules were large, distinct with prominent nuclei in control, however cells exposed to low dose & high dose exhibited cell shrinkage.

Exposure to high and low dose of NPK induced hyperplasia of mucous cells and excessive mucous secretion in gills compared to control. Exfoliation of epithelial cells in the lining of secondary lamellae was observed in both low and high dose compared to control. These cells were under the process of proliferation (Fig. 6A). In kidney, it was observed that control group showed large and distinct epithelial cells of renal tubules with prominent nuclei, however cells shrinkage was observed in both low dose and high dose (Fig. 6B).

DISCUSSION

Plethora of stressor affects the aquatic life due to the dependence on prevailing conditions of inhabited niche. Behavioural responses of fish to toxicant are the most sensitive indicators of potential toxic effects (EIFAC, 1983). The detection of abnormal activity is based on comparisons of the responses of exposed fish, either with activity measured during a baseline or pre-exposure period or observations of fish under a control treatment (Richmonds and Dutta, 1992). The loss of equilibrium, erratic swimming, sudden swimming motion and excessive mucus are the main responses of fish to fertilizers. The responses recorded in the present study are similar to those reported in literature under various stress conditions (Paul and Banerjee, 1996; Rani *et al.*, 1997; Palanivelu *et al.*, 2005; Ufodike and Onusiriuka, 2008). We observed a significant increase in VR as well as SA at low and high dose of NPK fertilizer. This may be due to NPK fertilizer induced oxygen depletion in blood and tissues, thus reducing the size of transportation channels of blood and nutrients. Stress induced by NPK may cause restricted water breathing to avoid excess influx of nitrogen, phosphate and potassium by gills and motion towards surfaces to accomplish respiratory needs.

Proteins are primary biomolecule essential for growth, differentiation and maintaining cellular homeostasis. Levels of proteins can serve as indicator of the physiological strategy adopted by the fish when it is in need of energy to adapt to the changed metabolic system. The decrease in the protein content as observed in the present study (Fig. 2A) in fish muscle tissues may be due to metabolic utilization of the ketoacids to gluconeogenesis pathway for the synthesis of glucose, or due to movement of the free amino acids for the synthesis of proteins, or for osmo and ionic regulation (Schmidt Nielson, 1975). Protein depletion in tissue may play a role of as a compensatory mechanism under stress, to provide intermediate for the kreb's cycle.

Carbohydrate is an important biochemical constituent of animal tissues. It acts as reserved food which is used as an immediate source of energy when required. The disturbance in the glycogen profile is one of the stupendous biochemical lesions due to the action of many toxicants. Depletion in glycogen level might be due to its rapid utilization to meet the energy demands under the stress condition (Sobha K, *et al.*, 2007). It is assumed that decrease in glycogen content may be due to the inhibition of hormones which contribute to glycogen synthesis. Decrease in muscle glycogen levels (Fig. 2B) is in correlation with the reports by earlier workers (Sobha K, *et al.*, 2007 ; Bedii and Kenan, 2005; Sastry and Subhadra, 1984). It appears to be through disruption of oxidative phosphorylation which causes interaction with the basic energy conservation system due to anoxic conditions of the tissue. The reduced oxygen transport causes tissues acidosis, favoured the process of glycogenolysis in tissues and the decrease in glycogen level might be due to anoxic condition since anoxia increases glycogen consumption to meet energy demand (Karat *et al.*, 2009). Lipids (constituting phospholipids, free fatty acids, free cholesterol, diglycerides, and triglycerides) are also the storage form of energy like glycogen. The lipid levels also decreased in the tissues (liver and muscle) of the fish exposed to the sub-lethal concentration of NPK which is in correlation with earlier work with other toxicants (Fig. 2C and D) (Levesque *et al.*, 2002; Fabien Pierron *et al.*, 2007; Sobha K, *et al.*, 2007). Lypolysis was more in liver than muscles. The reduction in the level of lipid is may be due to increased lypolysis of structural lipids to keep the metabolic processes maintained which causes alteration in normal homeostasis of the body. A significant increase in serum/plasma glucose level may be due to enhanced breakdown of glycogen to glucose through glycogenolysis under toxic stress of NPK. An increase in free cholesterol level of serum was correlated with a decrease in liver lipid (Fig. 3).

Nitric oxide (NO) is a major secretory product of chordates that initiates host defense, homeostatic and development functions by acting as secondary messenger. As a direct effector, NO induce activation of regulatory proteins, kinases, and proteases in a redox dependent manner. As a messenger molecule, NO covalently interacts with target molecules based on redox potential and generate cellular response. We observed that the serum NO level increases in low dose and even more in high dose in comparison to control (Fig. 4). The increased level of NO under stress condition indicates it role in maintenance of homeostasis as well as activation of immune system to combat environmental stress. Further, electrolytes are major players for maintenance of osmolarity of fish in different aquatic environment. Major electrolytes include Na^+ , K^+ , Cl^- and Ca^{2+} . Interestingly, we observed a biphasic response with significant increase in Ca^{2+} & drastic decrease of K^+ at low dose (Fig. 4B and C). This indicates physiological modulation in level of different electrolytes under stress in order to adapt to the changing environment.

The air breathing organ (ABO) of *H. fossilis* help in survival under desiccation and hypoxic condition in water. The important histopathological alterations observed in the ABO of *H. fossilis* due to NPK fertilizer include detachment and lifting of the respiratory epithelia from the underlying vascular components of the secondary lamellae and sloughing off viable epithelial cells (Fig. 5A), which results in haemorrhage into the lumen fuse causing reduction of volume of the lumen. Our observation is in correlation with findings of Rajan and Banerjee (1993) for histopathological damage to the air sac of *H. fossilis* exposed to a lethal concentration of mercuric chloride. The skin is a primary defensive organ of any organism. In *H. fossilis* exposed to NPK fertilizer, the club cells in the middle layer of skin show vacuolization and many other symptoms of necrosis. The disorganization of epithelial cell layer due to hyperplasia and breakdown of a crust of a dead layer of cells increases the barrier distance between dissolved oxygen in the media and blood in sub-epidermal blood vessels. Further, liver which is the primary organ for metabolism, detoxification of xenobiotics and excretion of many harmful substances was monitored for histological changes under NPK induced stress. The liver has the ability to degrade toxic components, but its regulating mechanisms can be overwhelmed by elevated concentrations of these compounds, and could subsequently result in histological changes and structural damage (Brusle J, *et al.*, 1996). High dose of NPK showed larger lesion area in liver than low dose.

Further, the histopathological study of gill under different sub-lethal doses of showed hyperplasia of primary and secondary lamellae, degeneration of epithelium, fusion of adjacent secondary lamellae, increased mucus production, secondary lamellae appeared thickened and shortened with extremely rough surface and considerable mucus in both low and high dose treatment. A similar observation was also made by Tandjung, Segner *et al.*, and Lamchumchang *et al.*, in brown trout, *Salmo trutta* and *Oreochromis niloticus*. Stress responses may also be evident in the kidney because of its prominent role in metabolism and maintain homeostasis. Often, quantitative alterations in renal energy storage are visible macroscopically as changes in kidney size and coloration (Wolf *et al.*, 2005). In conclusion, present study provides a detailed insight of the responses mounted by fishes to exogenous NPK fertilizer. It further provides an understanding of the impact of employing chemical fertilizers on aquatic life.

ACKNOWLEDGEMENT

Authors are grateful to Prof. Bechan Lal and Mr. Ankur Singh for constant guidance and support. Experimental facilities provided by Department of Zoology, BHU, Varanasi is humbly acknowledged.

CONFLICT OF INTEREST

There are no actual or potential conflicts of interest.

REFERENCES

- Altinok, I., Capkin, E., Karahan, S. and Boran, M. (2006). Effects of water quality and fish size on toxicity of methiocarb, acarbamate pesticide, to rainbow trout. *Environmental Toxicology Pharmacology*, 22: 20-26.
- Bedii CiCiK and Kenan ENGiN, (2005). The effects of Cadmium on levels of glucose in serum and glycogen reserves in the liver and muscle tissues of *Cyprinus carpio* (L., 1758). *Turk.J.Vet.Anim.Sci.*, 29: 113-117.
- Brusle, J. and Anadon, G. G. (1996). The Structure and Function of Fish Liver. In: *Fish Morphology*. Science Publishers, pp 77-93.
- Capkin, E., Kayis, S., Boran, H. and Altinok, I. (2010). Acute toxicity of some agriculture fertilizers to rainbow trout, *Oncorhynchus mykiss*. *Turkish J. Fisheries & Aquatic Sci.* 10: 19-25.
- Carroll, N.V., Longley, R.W. and Roe, J.H. (1956). The determination of glycogen in liver and muscle by use of anthrone reagent. *J. Biol. Chem.*, 220(2):583-93.
- Chowdhury, M.J., Pane, E.F. and Wood, C.M. (2004). Physiological effects of dietary cadmium acclimation and waterborne cadmium challenge in rainbow trout: respiratory, ionoregulatory, and stress parameters. *Comp Biochem Physiol C Toxicol Pharmacol.*, 139(1-3): 163-173.
- EIFAC (European Inland Fisheries Advisory Commission). (1983). Revised report on Fish Testing Procedures. EIFAC Tech. Pap. 24 Rev. FAO, Rome, 37 pp.
- Fischer, A.H., Jacobson, K.A., Rose, J. and Zeller, R. (2006). Hematoxylin and eosin staining of tissue and cell sections. In: Spector DL, Goldman RD (eds) *Basic Methods in Microscopy*. Cold Spring Harbor Laboratory Press, Cold Spring Harbor.
- Fabien, P., Magalie, B., Angélique, B., Jean-Paul, B., Daniel, B., Pierre, E. and Jean-Charles, M. (2007). Impairment of lipid storage by cadmium in the European eel (*Anguilla anguilla*). *Aquatic Toxicology*, 81(3): 304-311.
- Folch, J., Lees, M. and Stanley, G.H.S. (1957). A simple method for the isolation and purification of total lipides from animal tissues. *The Journal of Biological Chemistry* 226: 497-509.
- Jhingran, V.G., (1982). *Fish and Fisheries of India*. Delhi Hindustan Publishing Corporation, 666p.
- Kharat, P.S., Laxmi, B.G., Shejule, K.B. and Ghoble, B.C. (2009). Effect of TBTCCL on Glycogen Profile in Freshwater Prawn, *Macrobrachium kistnensis*. *World Applied Sciences Journal* 7 (12): 1534-1539.
- Lamchumchang, K., Jiraungkoorskul, W., Sahaphong, S., Tansatit, T., Kosai, P. and Madarasmii, R. (2007). Dietary calcium reducing effects of waterborne lead uptake in Nile Tilapia (*Oreochromis niloticus*). *AJAVA.*, 2: 104-114.
- Levesque, H.M., Moon, T.W., Campbell, P.G.C. and Hontella, A. (2002). Seasonal variation in carbohydrate and lipid metabolism in yellow Perch (*Perca flavescens*) chronically exposed to metals in the field. *Aquat Toxicol* 60:257-267.
- Lowry, O.H., Rosenbrough, N.J., Farr, R.L. and Randall, R.J. (1951). Protein measurement with the Folin Phenol reagent. *J.Biol.Chem.*, (193): 265-275.
- Meehan, O.L. and F. Marzulli. (1945). The relationship between the production of fish and the carbon and nitrogen contents of fertilized fish ponds. *Trans. Amer. Fish. Soc.*, 69: 257-262.
- Narain, A.S. and Srivastava, P.N. (1979). Haematohistological response of the Indian freshwater catfish, *Heteropneustes fossilis*, to environmental pollution of sewage, fertilizers and insecticides. *Arch. Biol. Bruxelles*, 90: 141-159.
- OECD (Organization for Economic Cooperation and Development). (1992). *Guideline for the Testing of Chemicals: Fish, Acute Toxicity Test No. 203*.
- Omeregic, E., Ajima, M.N.O. and Keke, I.R. (2003). Effect of Sub-lethal concentration of NPK (15:15:15) fertilizer on growth and feed utilization by the toothed carp *Aphyosemion gairdneri* under laboratory conditions. *J. Aqua. Sci.* 18 (2): 101-104.
- Palanivelu, V., Vijayavel, K., Ezhilarasi balasubramanian, S. and Balasubramanian, M.P. (2005). Impact of fertilizer (urea) on oxygen consumption and feeding the fresh water fish *Oreochromis mossambicus*. *Environmental Toxicology and Pharmacology*, 19: 351-355.
- Paul, V.I. and Banerjee, T.K. (1996). Ammonium sulphate induced stress related changes in the epidermis of the live fish *Heteropneustes fossilis* (Bloch). *J Fish Soc Taiwan* 23: 31-41.

- Rajan, M.T. and Banerjee, T.K. (1991). Histopathological changes induced by acute toxicity of mercuric chloride on the epidermis of a freshwater catfish *Heteropneustes fossilis* (Bloch). *Ecotoxicol Environ Safety* 22:139–152
- Rajan, M.T. and Banerjee, T.K. (1993). Histopathological changes induced by acute toxicity of mercuric chloride on the air- breathing organ (branchial diverticulum) of the livefish *Heteropneustes fossilis* (Bloch). *Acta Hydrochim Hydro- biol* 21:316–322
- Rani, E.F., Elumalai, M. and Balasubramanian, M.P. (1997). The toxicity of mixtures of monocrotophos and ammonium chloride to a fresh water fish *Oreochromis mossambicus*. *Biomedical Letters*. 55: 193–198.
- Richmonds, R.C. and Dutta, H.M. (1992). Effect of malathion on the brain acetylcholinesterase activity of blue gill sunfish *Lepomis macrochirus*. *Bull. Environ. Contam. Toxicol.*, 49: 431-435.
- Roeschlau, P., Bernt, E. and Gruber, W. (1974). Enzymatische Bestimmung des Gesampt-Cholesterins in serum. *J. Clin. Chem. Clin.Biochem.* 12, 226.
- Sastry, K.V. and Subhadra, K. (1982). Effect of cadmium on some aspects of carbohydrate metabolism in a freshwater catfish, *Heteropneustes fossilis*. *Toxicol. Lett.* 14: 45-55.
- Schmidt Nielson, B. (1975). Osmoregulation: Effect of Salinity and heavy metal. *Fed.Proc.* 33: 2137-2146.
- Segner, H., Mathaler, R. and Linnenbach, M. (1988). Growth aluminium uptake and mucous cell morphometrics of early life stages of bown trout, *Salmo trutta*, in low pH water. *Environ. Biol. Fish.*, 21: 153-159.
- Sobha, K., Poornima, A., Harini, P. and Veeraiah, K. (2007). A study on biochemical changes in the fresh water fish, *Catla catla* (hamilton) exposed to the heavy metal toxicant cadmium chloride. *KATHMANDU UNI. J. SCI. ENG. & TECH.* (1) No. IV.,
- Srivastava, P.N. and A.S. Narain. (1982). Leucocytic and haemaostatic reactions of the Indian catfish, *Heteropneustes fossilis*, subjected to environmental pollution by sewage, fertilizers and insecticides. *Acta Pharmacol. Toxicol.*, 50: 13-21.
- Sriwastawa, V.M. S. and Shivastava, D.K. (1977). Histochemical changes under urea stress in *Puntius sophore* (Hamilton). *Proceedings of All India Seminar on Ichthyology*, held on May 23-26, 1977 at Modinagar (U.P.), India, p.35.
- Tandjung, S.D. (1982). The Acute Toxicity and Histopathology of Brook Trout (*Salvelinus Fontinalis*, Mitchell) Exposed to Aluminum in Acid Water. Fordham University, New York, USA., Pages: 426.
- Tietz, N.W. (1976). *Fundamentals of Clinical Chemistry*. W. B. Saunders Company, Philadelphia, PA, pp. 874.
- Trinder, P. (1969). Determination of glucose in blood using glucose oxidase with an alternative oxygen acceptor. *Ann. Clin. Biochem.* 6:24–7.
- Ufodike, E.B.C. and Onusiriuka, B.C. (2008). Acute toxicity of inorganic fertilizers to African catfish, *Clarias gariepinus* (Teugals). *Aquaculture Research*, 21: 181-186.
- Uhuo, C.A., Nwele, D.E., Odikamnor, O.O., Ibiama, .A. and Azi, S.O. (2013). The Toxicity Effect of N. P. K. Agro-Fertilizer on *Oreochromis Niloticus* Fingerlings, the Pysiological Impact. *Journal of Biology, Agriculture and Healthcare.* (3) 5-9.
- Wolf, J.C. and Wolfe, M.J. (2005). A brief overview of nonneoplastic hepatic toxicity in fish. *Toxicol Pathol* 33:75-85.

ISSN : 0976-4550

INTERNATIONAL JOURNAL OF APPLIED BIOLOGY AND PHARMACEUTICAL TECHNOLOGY



Email : editor.ijabpt@gmail.com

Website: www.ijabpt.com