

Case Report

Femoral Fracture During Cesarean Section: A Case of Professional Liability? Case Presentation and Review of the Literature

Luigi Papi^{1*}, Federica Gori¹, Sara Turco¹, Alessandra Perutelli²

¹Department of Legal Medicine, University of Pisa, Italy

²Department of Obstetric and Gynecology, University of Pisa, Italy

***Corresponding Author:** Luigi Papi, Department of Legal Medicine, University of Pisa, Italy, via Roma 55, - 561126 PISA, Tel: 00390502218500; E-mail: luigi.papi@unipi.it

Received: 18 June 2019; **Accepted:** 04 July 2019; **Published:** 11 September 2019

Abstract

Breech foetuses are commonly delivered via caesarean section to prevent trauma and decrease the risk of head entrapment, though extraction by abdominal route can very rarely lead to traumatic femur fracture. Typical site of fracture is femoral diaphysis. Although femur fracture is a relatively rare complication, it represents one of the most common fractures of the lower extremity presenting in newborns. A 3900 g female child born at 39 weeks of gestation by caesarean section, presented swelling and tenderness of the left lower extremity in the second day of life. There was no apparent bone disorder predisposing to femur fracture. Fracture of left diaphysis was successfully treated by immobilization with Pavlik harness, healing in a good position for 23 days. Three months after birth, radiogram revealed regular bone consolidation and fracture fully welded. One year after birth, both lower limbs showed a proper mobility with no dysmetria. Caesarean delivery reduces increasingly traumatic complications, especially in breech delivery compared with vaginal delivery, but does not eliminate possible accidental injuries of the newborn. Predisposing factors are many, especially breech presentation and foetuses with malpresentation. Clinicians must be aware that abdominal delivery does not preclude the occurrence of femur fractures.

Keywords: Femur fracture; Breech presentation; Cesarean delivery

1. Introduction

Birth injuries presenting during the childbirth process are very rare, occurring in less than 1% of all live births [1, 2] and they are commonly associated with breech presentations and difficult deliveries [3, 4]. Three quarters of all birth-associated fractures of long bones are ascribed to vaginal breech deliveries [5]. Other risk factors include low birth weight and large foetuses [6]. Cesarean section has been reported to reduce almost completely the incidence of birth-associated injuries⁷ in new-borns with a variety of health complications [8, 9]. New-borns for whom are diagnosed with a fracture in the first week of life, in the absence of known post-natal trauma, are considered to have suffered a birth fracture, as it is known that difficult birth requires considerable traction can result in neonatal fractures [10].

Most common fractures during vaginal delivery usually involve the clavicle, humerus and femur [9,10]. Typical site of femoral fracture is the diaphysis, and consequentially the bone is dislocated in flexion and shortened due to the action of the longitudinal muscle [10]. Although femur fracture is a relatively uncommon injury, it represents the most common fracture of the lower extremity in the newborn [11]. Majority of neonatal femoral fractures occur during vaginal breech delivery. Nowadays cesarean section is commonly practiced in breech presentation [12,13] and, although it might reduce the occurrence of traumatic injury [13,14], femur and humerus fractures are still observed [14-17] showing that planning the cesarean section reduces the risk of fracture of long bones but does not eliminate its possibility at all [14]. The multicentre randomized study of Hannah and colleagues showed that the fracture of long bones occurred in 0.5% of cases during vaginal delivery and 0.1% during cesarean section [18]. If diagnosis is unrecognized or delayed, the fracture may go on to a wrong weld joint, causing angular or rotational deformity of the extremity [19].

Fractures of the femoral shaft resulting from birth-related trauma are extremely rare, although they have been reported to occur after difficult deliveries requiring considerable traction [21-23]. This kind of fractures has rapid healing with a short time of treatment [24] with a median time of healing of 30 days and no major complications are reported [25].

We present a case of left femoral shaft fracture in a new-born who presented swelling and tenderness of the left lower extremity on the second day of life. The case has come to our attention because infant's parents sued for malpractice the medical team who looked after the birth.

2. Case History

A 3900 g female infant, appropriate for gestational age, was born at 39 weeks by primary cesarean section secondary to breech presentation. The mother was a 30 years-old Caucasian primipara, with no history of previous uterine surgery. Pregnancy had far been uneventful with a normal second trimester obstetrics ultrasound and a clinical history negative for gestational problems. Membranes ruptured just before the birth and no cephalic version was attempted to correct the malpresentation. Through a lower segment transverse cesarean section, the obstetrician

did not encounter any difficulty in delivering the female baby who cried immediately at birth. Apgar scores were 9 at 1 and 5 minutes, respectively. After the extraction, the baby was subjected to careful clinical examination and routine laboratory tests that showed no abnormalities. Infant was doing well until the second day, when she became irritable and not interested in feeding; she was afebrile and there were no other infection-related signs.

On clinical examination, the infant's left lower extremity was uniformly swollen from the toes to the inguinal crease, in particular at thigh level. In addition, left inferior limb was shorter than the right, warm, tender to touch and painful during passive movements. Mobility was very decreased compared with the right. Left femoral pulses were felt to be diminished compared to the left side, whereas dorsalis pedis pulses were normal. Range of motion was normal at the hip without any evidence of hip instability or dislocation.

Radiographs revealed a femoral fracture of the shaft at the proximal level with displacement and angulation/displacing anteriorly compared to the middle and distal segment (Figure 1).

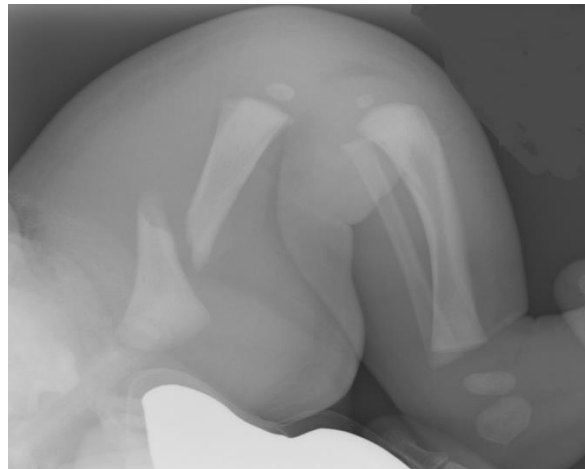


Figure 1: Radiograph shows displacement and angulation/displacing anteriorly compared to the middle and distal segment.

Whole body radiographs were performed and did not show fracture of any other bone. The bone structure and mineralization appeared normal; there was no indication of any other fracture/bone deformities or anomalies osteo-articular like blue sclera, osteogenesis imperfecta or hypotonia/Welding-Hofmann disease. The fracture was treated with immobilization with Pavlik harness and three weeks later, follow-up radiograph showed the formation of a callus at the margins of fracture and also an intense periosteal reaction at the femoral shaft so the immobilization was removed at 23 days after birth. On clinical examination the skin thigh appeared regular with no deformities and there was no dysmetria between the lower limbs. The child was able to move her left leg actively in all planes of space without length discrepancy.

Three months after birth, a further control radiogram revealed good healing with a regular bone consolidation and one year after birth, both lower limbs showed a proper mobility with no dysmetria, bilateral flat foot and regular vertebral column. The case came to our attention because it was subject of legal controversy. Parents of the female infant sued for malpractice the medical team who looked after the birth.

3. Discussion

Forced obstetric manoeuvres always carry a risk of soft-tissue injury, long-bones fractures and related neonatal complications [14]. Risk factors include both large and very small foetuses, breech presentation, difficult delivery, inadequate uterine relaxation, small uterine incision, twin pregnancies, prematurity, the advanced age of the mother, primipara status, osteogenesis imperfecta, and osteoporosis [3,26,27]. The most common fractures during vaginal delivery almost always involve the clavicle, humerus and femur [27]. Both vaginal and cesarean section, breech delivery and maneuvers such as external cephalic version were found to be responsible in birth traumas including long bone fractures [28]. In 1922, Ehrenfest first described a fracture of the femur in a newborn associated with a difficult breech extraction during cesarean section [29]. Historically, long-bone fractures have been long attributed to difficult deliveries, in particular to breech presentation, but they are remarkably rare [11]. The role of gender in fracture risk has not been assessed in the published literature.

Breech presentation occurs in 3% to 5% of all single pregnancies. The frequency is even higher in single preterm deliveries (10% to 15%) and twin pregnancies (25%) [30]. Breech presentation is associated with poorer perinatal and neonatal outcomes and is an independent risk factor for a higher neonatal mortality rate [31]. Many studies have shown a significant reduction in perinatal and infant mortality if term breech pregnancies are delivered by planned caesarean section [12-17, 32, 34]. While vaginal breech delivery, although rare, can cause femur fracture, only few reports have described femoral fracture when abdominal breech delivery is performed [22, 35, 36]. Such fracture are caused by forced, sudden traction with twisting and pulling manoeuvres or when the infant is improperly held by one thigh during delivery of the shoulders and arms [13, 26, 35].

Jain and Bielski have underlined how a history of cesarean section does not rule out the possibility of a fracture and proposed an appropriate extension to uterine incision in order to avoid greater amounts of traction on the extremities during obstetric manoeuvres [19]. Vasa and Kim described seven femoral shaft fractures that occurred during cesarean section [12]. Toker et al. reported one of the largest known series of twelve femur fractures after cesarean section (incidence of 0.308 per 1000) versus 5 fractures in vaginal delivery (incidence of 0.027 per 1000); they stated that the risk of caesarean-related femur fracture in newborns should not be underestimated [37]. In another study, Basha et al. have shown long-bone fractures were more frequently associated with caesarean breech delivery compared with vaginal deliveries; in their study, the incidence birth-related femur fracture was 0.17/1000 live births [2]. Morris et al., reported an estimated incidence of birth trauma of 0.13 to 1 per 1000 [1]; they also have suggested that most of the injuries occurred under general anaesthesia, which correlated with an inappropriate application of force during delivery, and how a good training and supervision of residents could implement safer delivery

techniques. Nadas et al., reported the most common risk factors as obstetric manoeuvres (75%), cesarean section (35%), prolonged labor (33%) and prematurity (25%) [38]. In Kancherla's study, ten cases of femoral fracture were described with 60% incidence in cesarean section, particularly predominant with breech presentation [38].

According to Morris and collaborators, the time span from delivery to diagnosis of femur fractures averaged 6.3 days, while the mean period reported by Kancherla is 4 days and by Basha 1.5 days, that it is similar to the time period in our case report. Soft tissue swelling, joint stiffness, focal tenderness and irritability often appear later, and may explain the delay in diagnosis. Since there are few data about the incidence of birth-related femoral fractures, no single treatment regimen for such injuries has been yet proposed. Common and recommended treatment methods reported in orthopaedics literature for femur fractures in neonates include: posterior splinting, spica cast, cast in flexion and abduction, gallow's traction, Bryant traction and Pavlik harness [40,41]. Only a single case of external fixator has been described [25].

Pavlik harness was the treatment modality used in our case. This treatment method achieves reduction by bringing the distal fragment in alignment with the proximal one; in addition, it lets the hospital stay to be minimized: in fact the female baby was discharged the day after the Pavlik harness was applied. Stannard and collaborators reported that fracture reduction is easily undertaken by adjusting the straps on the harness [40].

This kind of fractures rapid heal with a short time of treatment. All treatments are given good clinical and radiologic results within 1 month after injury and no major complications are reported.

In recent years there has been an exponential increase of charges against hospitals. From a medico-legal point of view, the case we reported is a very delicate condition because it may involve many health professionals as gynaecologists, obstetrics, neonatologists and also orthopaedics in the difficult case of professional medical liability. From the study of literature reviews and case reports and the analysis of the medical records of our case, femoral fracture in newborns with breech presentation occurring during cesarean delivery is a rare but possible injury. This kind of complication is not necessarily associated with improper obstetric manoeuvres; femur fractures can occur although the birth is performed accordingly to the most common science and medical knowledge. In addition, in all cases analysed in our literature review, fractures were successfully reduced in a short time, without further complications and with a very good recovery.

References

1. Morris S, Cassidy N, Stephens M, et al. Birth-associated femoral fractures: incidence and outcome. *J Pediatr Orthop* 22 (2002): 27-30.
2. Basha A, Amarin Z, Abu-Hassan F. Birth-associated long-bone fractures. *Int J Gynaecol Obstet* 123 (2013): 127-130.

3. Burke SW, Jameson VP, Roberts JM, et al. Birth fractures in spinal muscular atrophy. *J Pediatr Orthop* 6 (1986): 34-36.
4. Perlow JH, Wigton T, Hart J, et al. Birth trauma. A five-year review of incidence and associated perinatal factors. *J Reprod Med* 41 (1996): 754-760.
5. Curran JS. Birth-associated injury. *Clin Perinatol* 8 (1981): 111-129.
6. Kancherla R, Sankineani SR, Naranje S, et al. Birth-related femoral fracture in newborns: risk factors and management. *J Child Orthop* 6 (2012): 177-180.
7. Bistoletti P, Nisell H, Palme C, et al. Term breech delivery. Early and late complications. *Acta Obstet Gynecol Scand* 60 (1981): 165-171.
8. Farikou I, Bernadette NN, Daniel HE, et al. Fracture of the Femur of A Newborn after Cesarean Section for Breech Presentation and Fibroid Uterus : A Case Report and Literature Review. *J Orthop Case Rep* 4 (2014): 18-20.
9. Awari BH, Al-Habdan I, Sadat-Ali M, et al. Birth associated trauma. *Saudi Med J* 24 (2003): 672-674.
10. Caviglia H, Garrido CP, Palazzi FF, et al. Pediatric fractures of the humerus. *Clin Orthop Relat Res* 432(2005): 49-56.
11. Banagale RC. Neonatal fracture and cesarean section. *Am J Dis Child* 137 (1983): 505.
12. Vasa R, Kim MR. Fracture of the femur at cesarean section: case report and review of literature. *Am J Perinatol* 7 (1990): 46-48.
13. García García IE, de la Vega A, García Frago L. Long bone fractures in extreme low birth weight infants at birth: obstetrical considerations. *P R Health Sci J* 21 (2002): 253-255.
14. Canpolat FE, Köse A, Yurdakök M. Bilateral humerus fracture in a neonate after cesarean delivery. *Arch Gynecol Obstet* 281 (2010): 967-969.
15. Dunkow P, Willett MJ, Bayam L. Fracture of the humeral diaphysis in the neonate. *J Obstet Gynaecol* 25 (2005): 510-511.
16. Linder N, Linder I, Fridman E, et al. Birth trauma--risk factors and short-term neonatal outcome. *J Matern Fetal Neonatal Med* 26 (2013): 1491-1495.
17. Ogbemudia AO, Ogbemudia EJ. Emergency caesarean delivery in prolonged obstructed labour as risk factor for obstetric fractures--a case series. *Afr J Reprod Health* 16 (2012): 119-122.
18. Hannah ME, Hannah WJ, Hewson SA, et al. Planned caesarean section versus planned vaginal birth for breech presentation at term: a randomised multicentre trial. Term Breech Trial Collaborative Group. *Lancet* 356 (2000): 1375-1383.
19. Jain R, Bielski RJ. Fracture of lower femoral epiphysis in an infant at birth: a rare obstetrical injury. *J Perinatol* 21 (2001): 550-552.
20. Dalton HJ, Slovis T, Helfer RE, et al. Undiagnosed abuse in children younger than 3 years with femoral fracture. *Am J Dis Child* 144 (1990): 875-878.

21. Alexander J, Gregg JE, Quinn MW. Femoral fractures at caesarean section. Case reports. *Br J Obstet Gynaecol* 94 (1987): 273.
22. Barnes AD, Van Geem TA. Fractured femur of the newborn at cesarean section. A case report. *J Reprod Med* 30 (1985): 203-205.
23. McCollough FL, McCarthy RE. Bilateral distal femoral epiphyseal fractures following home delivery: a case report. *J Ark Med Soc* 84 (1988): 364-366.
24. Podeszwa DA, Mooney JF, Cramer KE, et al. Comparison of Pavlik harness application and immediate spica casting for femur fractures in infants. *J Pediatr Orthop* 24 (2004): 460-462.
25. D'Andrea L, Catena N. Femoral shaft fracture in a newborn infant treated with axial external fixator: a case report. *J Pediatr Orthop* 28 (2008): 17-19.
26. Awwad JT, Nahhas DE, Karam KS. Femur fracture during cesarean breech delivery. *Int J Gynaecol Obstet* 43 (1993): 324-326.
27. Kellner KR. Neonatal fracture and cesarean section. *Am J Dis Child* 136 (1992): 865.
28. Papp S, Dhaliwal G, Davies G, et al. Fetal femur fracture and external cephalic version. *Obstet Gynecol* 104 (2004): 1154-1156.
29. Ehrenfest H. Birth injuries of the child. New York: Appleton Century Crofts 1922:208.
30. Vidovics M, Jacobs VR, Fischer T, et al. Comparison of fetal outcome in premature vaginal or cesarean breech delivery at 24-37 gestational weeks. *Arch Gynecol Obstet* 290 (2014): 271-281.
31. Hofmeyr GJ, Hannah ME. Planned caesarean section for term breech delivery. *Cochrane Database Syst Rev.* (3): CD000166. Review. Update in: *Cochrane Database Syst Rev.* 2015;7:CD000166.
32. Ghosh MK. Breech presentation: evolution of management. *J Reprod Med* 50 (2005): 108-116.
33. Gilbert WM, Hicks SM, Boe NM, et al. Vaginal versus cesarean delivery for breech presentation in California: a population-based study. *Obstet Gynecol* 102 (2003): 911-917.
34. Kotaska A, Menticoglou S, Gagnon R, et al. Maternal Fetal Medicine Committee; Society of Obstetricians and Gynaecologists of Canada. Vaginal delivery of breech presentation. *J Obstet Gynaecol Can* 31 (2009): 557-566, 567-578.
35. Matsubara S, Izumi A, Nagai T, et al. Femur fracture during abdominal breech delivery. *Arch Gynecol Obstet* 278 (2008): 195-197.
36. Capobianco G, Viridis G, Lisai P, et al. Cesarean section and right femur fracture: a rare but possible complication for breech presentation. *Case Reports in Obstetrics and Gynecology* 2013: 1-3.
37. Toker A, Perry ZH, Cohen E, et al. Cesarean section and the risk of fractured femur. *Isr Med Assoc J* 11 (2009): 416-418.
38. Nadas S, Gudinchet F, Capasso P, et al. Predisposing factors in obstetrical fractures. *Skeletal Radiol* 22 (1993): 195-198.
39. Kancherla R, Sankineani SR, Naranje S, et al. Birth-related femoral fracture in newborns: risk factors and management. *J Child Orthop* 6 (2012): 177-180.

40. Stannard JP, Christensen KP, Wilkins KE. Femur fractures in infants: a new therapeutic approach. *J Pediatr Orthop* 15 (1995): 461-466.
41. Givon U, Sherr-Lurie N, Schindler A, et al. Treatment of femoral fractures in neonates. *Isr Med Assoc J* 9 (2007): 28-29.

Citation: Luigi Papi, Federica Gori, Sara Turco, Alessandra Perutelli. Femoral Fracture During Cesarean Section: A Case of Professional Liability? Case Presentation and Review of the Literature. *Archives of Clinical and Medical Case Reports* 3 (2019): 242-249.



This article is an open access article distributed under the terms and conditions of the [Creative Commons Attribution \(CC-BY\) license 4.0](https://creativecommons.org/licenses/by/4.0/)