

Review Article

Intra-Hepatic Semi-Rigid Ureteroscopy-when Convention Fails

Gaurav Aggarwal^{1*}, Sujoy Gupta¹, Sudeep Banerjee², Manas Kumar Roy²

¹Department of Urological-Oncology, Tata Medical Center, Kolkata, India

²Department of Gastrointestinal-Oncology, Tata Medical Center, Kolkata, India

***Corresponding Author:** Gaurav Aggarwal, Department of Urological-Oncology, Tata Medical Center, Kolkata-700156, India, Tel: 07873947779; E-mail: dr_gaurav1981@rediffmail.com

Received: 26 June 2019; **Accepted:** 11 July 2019; **Published:** 15 July 2019

Abstract

Intra hepatic biliary calculi form the Achilles' heel for a gastroenterologist. With an incidence of only 2%, literature on their management is sparse, especially when conventional methods fail. Though a low reported incidence, their onset is an epiphenomenon for cholestasis, cholangitis, sepsis as well as a fervent morbidity, if left untreated. Endourological advancements in technology, equipment as well as surgical-expertise, have laid open a new corridor for the role of the urologist, outside of the normal urinary tract. In this article, we review the available literature on the role of semi rigid ureteroscopy for clearance of intra hepatic biliary calculi/sludge, when conventional techniques have fallen short of expectations.

Keywords: Semi-rigid ureteroscopy; Intra hepatic calculi; Endourology; Biliary sludge; Ureteroscope

1. Introduction

Intra hepatic biliary calculi form the Achilles' heel for a gastroenterologist. With an overall incidence of 2% [1] literature on their management is sparse, especially when conventional methods fail. Though a low reported incidence, their onset is an epiphenomenon for cholestasis, cholangitis and sepsis, if left untreated [2]. Endourological advancements in technology, equipment as well as surgical-expertise, have laid open a new corridor for the role of the urologist, outside of the normal urinary tract. In this review, we report on the role of semi rigid ureteroscopy for clearance of intra hepatic biliary calculi/sludge, when conventional techniques have fallen short of expectations.

2. Materials and Methods

A thorough Pubmed search was done, with the MeSH terms “semi rigid ureteroscopy”, “rigid ureteroscopy”, and

“endourology and biliary stones”. Only articles that had all of these terms were included in the review. The literature search revealed a paucity of information on this account, with only three articles mentioning the use of semi rigid ureteroscopy and intra hepatic or biliary stone management and these were included in this review.

3. Intra-Hepatic Biliary Stone Formation and Associated Morbidity

The exact reason behind the formation of intra hepatic sludge and stones has not been pinpointed, however multiple theories have been put forth. Kochhar G, et al. [3] suggest that anything which increases biliary viscosity or predisposes to biliary outflow obstruction can predispose to the formation of sludge and stones. Ischemia, infection, immunosuppression, obstruction or biliary mucosal inflammation, due to any cause, may predict future stone formation [1, 3]. Multivariate analyses have confirmed the role of biliary outflow obstruction as well as hepatocellular diseases as predictive factors for new-onset biliary stone formation [2]. Irrespective of the underlying etiopathogenesis, these biliary calculi are a known cause of significant morbidity on account of cholestasis, cholangitis, strictures, abscess formation, post obstructive atrophy, biliary cirrhosis, portal hypertension as well as long term septicemia [1-4].

4. Conventional Modalities for Biliary Stone Clearance

Conventional treatment modalities for biliary stone disease include endoscopic retrograde cholangiopancreatography (ERCP), percutaneous transhepatic cholangiography (PTC), extracorporeal shock wave lithotripsy (ESWL), video-laparoscopy and open surgery [5, 6]. The choice of treatment varies in accordance with the patient’s clinical condition, anatomo-morphology of the calculus as well as the accessibility of the calculus based on its location in the biliary tree [7]. Despite treatments, recurrence of calculi is seen in approximately 30 percent cases, with 18.7% needing re-operation and 6.8% developing secondary biliary cirrhosis [8]. With the advent of minimally invasive surgical approaches, extra-hepatic biliary calculi are being easily dealt with and percutaneous approaches to intra-hepatic calculi have also begun gaining momentum [9]. Their potentially low risk: benefit ratio, coupled with urological expertise (in a multidisciplinary approach) have now waylaid them as safe and effective treatment options for recalcitrant biliary calculi, especially when conventional methods fail [9, 10].

5. When Convention Fails-Role of Endourology

Endourological expertise outside the genito-urinary system is often called upon, when conventional treatment methods fall short of expectations. This could be due to the difficult intra-hepatic location or numbers of calculi as well as thick inspissated sludge, difficult to excavate out via standard methods. Rajaian S, et al. [10] in 2006, report the case of a 43 year old lady with cholangitis and multiple left hepatic ductal calculi, following the excision of a Type IV choledocal cyst with choledocolithotomy and hepaticojejunostomy done 5 years prior. Following failure of conventional methods, the urological team used their 8/9.5 Fr Wolfe semi-rigid ureteroscope (access gained via a small enterotomy at the hepatico-jejunostomy site) and via pneumatic lithotripsy (with a Swiss Lithoclast Master), were able to achieve a 100% stone fragmentation, with the fragments passing out per naturalis. Hong, et al. [11] in 2007, report two similarly managed cases, following ERCP failure, with a 100% success rate.

The largest available literature however, lies with Sninsky BC, et al. [12]. This was a retrospective review, done in 2014, which included 13 patients in whom ERCP, PTC or both failed due to the inaccessibility of the calculi. Stone clearance required 1-2 procedures with a total clearance achieved in 12/13 (93%) patients; 62% after one procedure and 31% after two procedures. One patient with biliary cast syndrome was reported to need four interventions over 9 years. Only one patient was reported to have had hypotension and cholangitis that resolved with 24 hours, with conservative management [12]. In all of the above, percutaneous access of the biliary tract was attained depending on the anatomical topography of the underlying pathology, viz. trans-hepatic, trans-jejunal, etc. [10-12]. The advantage of using a semi-rigid ureteroscope lies in its good extent of flexibility and tapered tip, that helps to negotiate even acute angled ducts and additionally there is no image distortion or ductal damage [10]. Moreover, being a minimally invasive approach, there is less morbidity, which in turn reduces in-hospital stay as well as costs significantly, with very high success rates (93-100%) [10-14]. Figure 1 shows the view from a semi rigid ureteroscope within the intra-hepatic bile ducts.

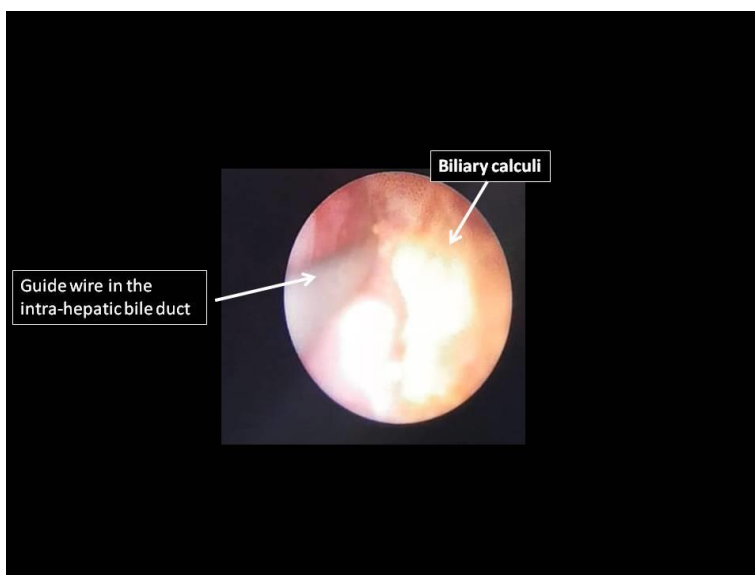


Figure 1: View from a semi rigid ureteroscope within the intra-hepatic bile ducts.

Table 1 highlights the available literature till date, on the use of semi-rigid ureteroscopy for clearance of intra-hepatic biliary calculi.

Author	Year	n	Condition treated	Indication	Equipment used	Energy source used	Success Rate	Complication
Rajaian S et al. [10]	2006	1	Biliodigestive anastomotic stenosis with calculi	ERCP and ESWL Failure	Semi rigid ureteroscope (Wolfe 8/9.8 Fr)	Pneumatic	100%	-

Hong et al. [11]	2007	2	Biliodigestive anastomotic stenosis with calculi	ERCP failure	Semi rigid ureteroscope	Not described	100%	-
Sninsky BC et al. [12]	2014	13	Biliary calculi, post bilio-digestive surgery	ERCP/PT C failure	Semi rigid ureteroscope	Electrohydraulic	93%	Hypotension and cholangitis (1 patient)

Table 1: Literature on Semi-rigid ureteroscopy and Intra-hepatic biliary calculi clearance.

6. Future Trends

Improvements in technology as well as urological expertise in the management of urinary tract stone disease have spilled over to non-urological systems as well. Management of complex biliary tract stone disease via hybrid approaches, involving endourology is now considered safe, effective and efficacious, especially when conventional approaches fail. An “out of the box” approach is mandated when standard methodology becomes sub-standard, on account of anatomic-pathological shortcomings. For the future, would it thus be safe to say that Endo-biliary urology could become an emerging super-specialization? Is the art of intra-hepatic ureteroscopy novel or plainly stated non-sensical? Could Endourology be applied to cure difficult access intra-hepatic biliary strictures as well?.

7. Conclusion

Urological expertise is thus sacrosanct, even in non-urological procedures, and a multi-disciplinary approach with endourological expertise should be considered when convention falls short of expectations, especially in complex endo-biliary conditions.

Source of Funding

Nil

Conflict of Interest

Nil

References

1. Pfau PR, Kochman ML, Lewis JD, et al. Endoscopic management of post operative biliary complications in orthotopic liver transplantation. *Gastrointest Endosc* 52 (2000): 55-63.
2. Maggi U, Paone G, Lauro R, et al. Holmium intraductal laser lithotripsy of biliary stones in liver grafts. *Transplantation Proceedings* 48 (2016): 380-382.
3. Kochhar G, Parungao JM, Hanouneh IA, et al. Biliary complications following liver transplantation. *World J Gastroenterol* 19 (2013): 2841-2846.

4. Fan ST, Lai EC, Wong J. Hepatic resection for hepatolithiasis. *Arch Surg* 128 (1993): 1070-1074.
5. Ponsky LE, Geisinger MA, Ponsky JL, et al. Contemporary “urologic” intervention in the pancreaticobiliary tree. *Urology* 57 (2001): 21-25.
6. Healy K, Chamsuddin A, Spivey J, et al. Percutaneous endoscopic holmium laser lithotripsy for management of complicated biliary calculi. *JLSLS* 13 (2009): 184-189.
7. Korkea F, Carneiro A, Nasser F, et al. Percutaneous treatment of complex biliary stone disease using endourological technique and literature review. *Einstein* (2014): 1-4.
8. Wolf JS Jr, Stoller ML. Applications of Urological techniques to nonurinary calculi. *Urology* 36 (1990): 383-389.
9. Nadler RB, Rubeinstein JN. Percutaneous Hepatolithotomy, The northwestern experience. *J Endourology* 16 (2002): 293-297.
10. Rajaian S, Mukherjee A, Gopalakrishnan G. A Novel Use of Semi Rigid Ureteroscope for a Non Urological A Point of Technique. *Kuwait Medical Journal* 38 (2006): 56-58.
11. Hoang JK, Little AF, Clarke A. Percutaneous intracorporeal lithotripsy of biliary calculi. *Australas Radiol* 51 (2007): 324-327.
12. Sninsky BC, Sehgal PD, Hinshaw JL, et al. Expanding endourology for biliary stone disease: the efficacy of intracorporeal lithotripsy on refractory biliary calculi. *J Endourol* 28 (2014): 877-880.
13. Stage JG, Moesgaard F, Gronvall S, et al. Percutaneous transhepatic cholelithotripsy for difficult common bile duct stones. *Endoscopy* 30 (1998): 289-292.
14. Wolf JS Jr, Nakada SY, Aliperti G, et al. Washington University experience with extracorporeal shock-wave lithotripsy of pancreatic duct calculi. *Urology* 46 (1995): 638-642.

Citation: Gaurav Aggarwal, Sujoy Gupta, Sudeep Banerjee, Manas Kumar Roy. Intra-Hepatic Semi-Rigid Ureteroscopy- when Convention Fails. *Journal of Surgery and Research* 2 (2019): 60-64.



This article is an open access article distributed under the terms and conditions of the

[Creative Commons Attribution \(CC-BY\) license 4.0](https://creativecommons.org/licenses/by/4.0/)