


Research Article

Musculoskeletal Manifestations among Egyptian HCV Patients Receiving Direct Antivirals (DAAS) Therapy

Marwa A Besar^{1*}, Adel Abd El salam², Asmaa F Enin³, Doaa A Anter⁴, Abeer saad Ali El zekred⁵

Abstract

Introduction: Hepatitis C is a worldwide problem; the treatment of chronic HCV has been revolutionized with the introduction of the oral Direct-Acting Antiviral (DAA) drugs. The efficacy in eradication of extrahepatic and hepatic manifestation leads to its widely spread of these medications, but there is musculoskeletal side effect reported with its use.

Objectives: Assess musculoskeletal manifestation in HCV patients receiving Direct Antivirals Therapy (DAATs) attending Rheumatology & Immunology Unit in internal medicine department in Mansoura university Hospital.

Result: Majority of studied patients (n=200) were 64% females and 36% were male. The most frequent involved joint was the knee 55% (110), while the least affected joint was the wrist 6% (12) and the shoulder joint 8%. It was observed that bone pain (71.1%) especially at shoulder joint (64.3%) and back (60.7%) were associated with Sofosbuvir+ Daclatasvir but were statistically insignificant. Arthralgia was presenting manifestation in 63% with patients received Sofosbuvir +Daclatasvir and dominated in the wrist joint (66.7%), knee joint (65.5%), shoulder joint (62.5%) but it was statistically insignificant. Back pain was evident in patients treated by DAAs for 12 weeks (27.7%) than those received it for 24 weeks (11.8%) and it was statistically significant $p^* = 0.050$.

Conclusion: Musculoskeletal disorders reported mainly with sofosbuvir and daclatasvir especially for 12-week duration and the most affected age group (more than 55year).

Keywords: Direct antiviral therapy (DAAS); HCV patients; Musculoskeletal manifestation; Arthralgia; Arthritis; Keratoconjunctivitis Sicca

Abbreviation: DAAS: Direct antiviral therapy; HCV: Hepatitis C virus; PCR: Polymerase Chain Reaction; SOF: Sofosbuvir; DCV: Daclatasvir; RBV: Ribavirin; NCCVH: Egyptian National Committee for Control of Viral Hepatitis

Background

Hepatitis C is a worldwide problem. The hepatitis C virus (HCV) is a major cause of both acute and chronic hepatitis. The World Health Organization (WHO) estimates about 71 million people globally have chronic hepatitis C, with approximately 399,000 dying from this infection, primarily due to cirrhosis and hepatocellular carcinoma (HCC) [1]. The treatment of chronic HCV has been revolutionized with the introduction of the oral direct-acting antiviral (DAA) drugs, since the introduction of DAAs therapy lead to HCV eradication and complete virologic response, but there are few studies that have investigated the efficacy and safety of these drugs on HCV-related extra-hepatic manifestations.

Affiliation:

¹Lecturer of Internal Medicine, Rheumatology & Immunology Unit, Faculty of Medicine, Mansoura University, Egypt

²Professor of Internal Medicine, Rheumatology & Immunology Unit, Faculty of Medicine, Mansoura University, Egypt

³Assistant Professor of Internal Medicine, Rheumatology & Immunology Unit, Faculty of Medicine, Mansoura University, Egypt

⁴Resident Of Internal Medicine At General Dekirnis Hospital, MBB Ch, Faculty of Medicine, Mansoura University, Egypt

⁵Department of biochemistry Specialized medical hospital, Egypt

*Corresponding author:

Marwa A Besar, Lecturer of Internal Medicine, Rheumatology & Immunology Unit, Faculty of Medicine, Mansoura University, Egypt.

Citation: Marwa A Besar, Adel I Abd El Salam, Asmaa F Enin, Doaa A Anter. Musculoskeletal Manifestations among Egyptian HCV Patients Receiving Direct Antivirals (DAAS) Therapy. Fortune Journal of Rheumatology 4 (2022): 25-33.

Received: October 27, 2022

Accepted: November 17, 2022

Published: December 01, 2022

Subject and Methods

Prospective randomized study on 200 Egyptian HCV patients complaining from musculoskeletal manifestation after receiving direct antiviral therapy (DAAs) for either 12 or 24 weeks duration therapy attending Rheumatology & Immunology Unit in internal medicine department in Mansoura university over a period of one year.

Methods

- Complete demographic and clinical assessment of HCV patients received direct antiviral (DAAs) therapy.
- Assessment of direct antiviral (DAAs) therapy; which type patient received, duration of treatment, side effect related especially on musculo-skeletal system.
- Rheumatological examination; large joints with special attention for (knee, hip, shoulder) and small joints with special attention for (wrist, foot).
- Full laboratory (CBC, LFT, s creatinine, ESR, CRP, RF,..) if arthritis is dominated finding.
- Radiological assessment of involved joint by plain Xray.
- Correlation of clinical finding, joint involved, laboratory and radiological finding with direct antiviral (DAAs) therapy.
- The age of studied patients in the current work was taken at the time of diagnosis. Age group was divided into 3 tertials; first tertials (I) = age group less than 35 years, second tertials (II) =age group (35-55) years, third tertials (III)= age group more than 55 years.

Inclusion criteria

All HCV patients (200) received direct antiviral therapy, presented with musculoskeletal manifestation during the period of study

Exclusion criteria

- Those who had any musculoskeletal manifestation before receiving antiviral therapy.
- Patients known to had Rheumatological disease (RA, SLE, Scleroderma,..).
- Patients with Hepatoma.

Sample size

Sample size calculation was based on clinical diagnostic criteria of ACR, EULAR, 2010 criteria of assessment of arthritis and other musculoskeletal manifestation.

Statistical analysis

After collection of the data, they were analyzed using the statistical package of social science (SPSS, IBM) software

version 25. Categorical data were expressed as numbers and percentages and were analyzed by Chi-square. P value was considered significant if it was < 0.05.

Result

Table (1) showed sociodemographic data of studied patients; Majority of studied patients (n=200) were females 128(64%) and 72 (36%) were male, 88% (176) of patients were non-smokers and 96 % (192) of them were married. Most of them 55 % (110) of patients were employed. Regarding age of patients 24(12%) of patients were less than 35 years old,110 of patients (55%) were 35-55 years old and 66 of patients (33%) were 55 years old.

Table 2 displays HCV status diagnosed by PCR: Majority of studied HCV patients 124 (62%) had no complications (cirrhotic liver, ascites and varices).Treatment by combination therapy (Sofosbuvir+Daclatasvir) in 126(63%) of HCV patients followed by 72(36%) treated by triple therapy (Sofosbuvir+ Daclatasvir+ Ribavirin) with only 2(1%) of them treated by combination therapy (Sofosbuvir +Simeprevir). Duration of treatment was 12 weeks in 166 (83%) of HCV patients and 24 weeks in 34(17%) of them. Complete remission was achieved in 198(99%) of the patients.

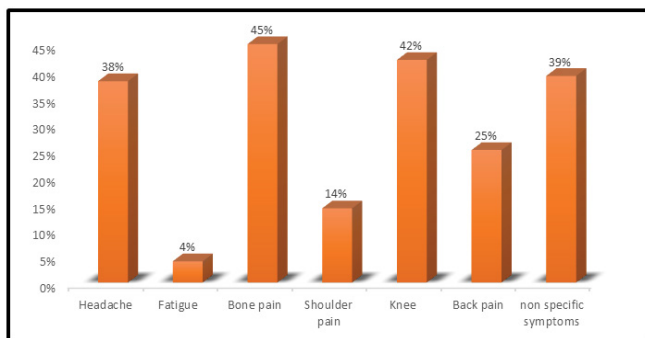
Figure (1) display that most of the studied patients 45%(90) complained from bone pain followed by 42%(84) complained from knee pain followed by 39%(78) complained

Table 1: Socio demographic characteristics of studied patients (n=200).

Characteristics (n=200)	Frequency	Percentage (%)
Sex		
Male	72	36
Female	128	64
Age (years)		
<35	24	12
35-55	110	55
>55	66	33
Smoking habit		
non-smoker	176	88
Smoker	24	12
Marital status		
Not married	8	4
Married	192	96
Occupation		
Unemployed	110	55
Employed	90	45

Table 2: HCV status diagnosed by PCR (n=200).

	Frequency	Percentage (%)
Complications		
No complications	124	62%
Complications	76	38%
DDA_ treatment		
Sofosbuvir+ Daclatasvir	126	63%
Sofosbuvir+Daclatasvir+Ribavirin	72	36%
Sofosbuvir +Simeprevir	2	1%
Duration of DAA treatment(weeks)		
12 weeks	166	83%
24 weeks	34	17%
Responsiveness to treatment		
No Responsiveness	2	1%
Cured	198	99%



*Categories are not mutually exclusive

Figure 1: Complaints of the HCV patients (n=200).

from nonspecific symptoms (any symptoms other than previous mentioned) followed by 38% (76) complained from headache followed by 25%(50) complained from back pain followed by 14%(28) complained from shoulder pain followed by 4% (8) complained from fatigue.

Figures (2): showed distribution of joints affected. The most frequent involved joint was the knee 55% (110), while the least affected joint was the wrist 6% (12) and the shoulder joint 8% (16) with more than 30% of patients had more than one joint affected. Majority of studied patients 85% (166) had progressive course and 15% of them had stationary course.

Figures 3 displays results of radiological findings of affected joints; Osteopenia in more than one site (knee, hip, shoulder, foot) was detected in 150(75%) of HCV patients, 55% of them had joint narrowing in more than one site(hip, knee, wrist, shoulder) followed by knee joint narrowing in 76(38%)of the patients. Knee osteophytes was evident in 54(27%) of the patients.

Table 3 displayed results of ocular findings of HCV patients. Most frequent symptom was dryness in 66 (33%) HCV patients followed by conjunctivitis in 40(20%) of them, of them only 4 (2%) were assessed by fundus examination and 16(8%) of them received eye drops while 10(5%) received intervention.

Table 4 Association between DAA and patients' complaints displays results association between DAA and patients' complaints :- It is noticed fatigue associated with Sofosbuvir, Daclatasvir +Ribavirin and it is statistically significant ($p^* = 0.001$).headache (57.9%) and bone pain (71.1%) especially at shoulder joint (64.3%) and back(60.7%) were associated with Sofosbuvir+ Daclatasvir but were statistically insignificant. Arthralgia was presenting manifestation in 63% with patients received Sofosbuvir +Daclatasvir and dominated in the wrist joint (66.7%), knee joint (65.5%), shoulder joint (62.5%) but it was statistically insignificant.

The main clinical presentation was joint swelling in 100% of patients treated with Sofosbuvir, Daclatasvir than received Sofosbuvir, Daclatasvir +Ribavirin (0%) but it was statistically insignificant. Joint erythema and tenderness were found in (66.7%) and (60%) in patients received (Sofosbuvir+ Daclatasvir), (Sofosbuvir, Daclatasvir +Ribavirin) respectively but it was statistically insignificant.

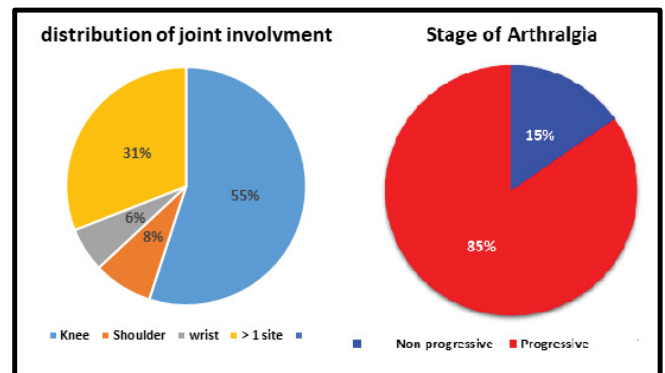


Figure 2: Distribution of joint involvement & Stage of Arthralgia.

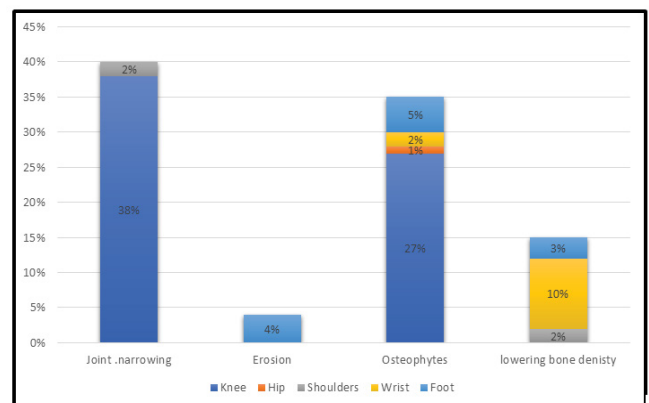


Figure 3: Radiological Assessment (X-Ray) of affected joints.

Limited joint mobility was common in patients treated with (Sofosbuvir+ Daclatasvir)(52%) than patients received (Sofosbuvir, Daclatasvir +Ribavirin) (48%) and it was statistically significant $P^* < 0.006$. Radiological assessment of affected joint (plain- x ray) showed that joint narrowing was the most finding in 62.1% of patients, followed by osteopenia 60.4%, erosion 51% of HCV patients treated by (Sofosbuvir+ Daclatasvir) than received (Sofosbuvir, Daclatasvir +Ribavirin), 36.8%,38.5%, 49% respectively but it was statistically insignificant. Osteophytes was detected in 53.8% of HCV patients treated by (Sofosbuvir+ Daclatasvir) than those treated by (Sofosbuvir, Daclatasvir +Ribavirin)

Table 3: Ocular symptoms of HCV patients (n=200).

Ocular assessment	Frequency	Percent
SICCA(dryness)	66	33
Conjunctivitis	40	20
Fundus	4	2
Eyedrops	16	8
Surgical Intervention	10	5

43.6% and (Sofosbuvir +Simeprevir) 2.6% and it was statistically significant $P^*=0.032$.

Table (5) showed that Headache shows significant difference between patients received DAAs treatment for 24 weeks (52.9%) than 12 weeks (34.9%) and it was statistically significant $p^* = 0.039$. Patients treated by DAAs therapy for about 24 weeks show fatigue (5.9%) bone pain (47.1%), knee pain(47.1%) than treated it for 12 weeks (3.6%),(44.6%),(41%) respectively and it was statistically insignificant. Back pain was evident in patients treated by DAAs for 12 weeks (27.7%) than those received it for 24 weeks (11.8%) and it was statistically significant $p^* = 0.050$. no significant differences in clinical joint assessment of the HCV patients between 12 weeks and 24 weeks DAA treatment and it was statistically insignificant ($p > 0.05$).

Table (6) showed that Joint tenderness was the commonest presentation in different age groups < 35 years (91.7%), age group between 35-55 years(100%) , age group >55 years(100%) patients and it was statistically significant $p^* = 0.001$

Table 4: Association between DAA and clinical assessment of HCV patients (n=200)

		DDA treatment			Pearson Chi-Square	Sign p^*
		Sofosbuvir+ Daclatasvir	Sofosbuvir, Daclatasvir +ribavirin	Sofosbuvir +Simeprevir		
Headache No (%)		44 (57.9%)	32 (42.1%)	0	3.002	0.223
Fatigue No (%)		0	8 (100%)	0	14.815	0.001
Bone pain. No (%)		64 (71.1%)	26 (28.9%)	0	5.644	0.059
Shoulder pain.No (%)		18 (64.3%)	10 (35.7%)	0	0.335	0.846
Back pain No (%)		56 (60.7%)	44 (37.7%)	0	2.37	0.306
Arthralgia No (%)		126 (63%)	72 (36%)	2 (1%)	2.37	0.306
Site of arthralgia	knee	72 (65.5%)	36 (32.7%)	2 (1.8%)	2.975	0.812
No (%)	Shoulder	10 (62.5%)	6 (37.5%)	0		
	Wrist	8 (66.7%)	4 (33.3%)	0		
	>1 sites	36 (58.1%)	26 (41.9%)	0		
Joint examination						
Joint swelling No (%)		4 (100%)	0	0	2.67	0.262
Joint erythema No (%)		4 (66.7%)	2 (33.3%)	0	0.15	0.922
Joint tenderness No (%)		108 (60%)	70 (38.9%)	2 (1.1%)	1.324	0.516
Limited joint mobility. No (%)		52 (52%)	48 (48%)	0	10.305	0.006
Radiological evolution of affected joint						
Joint narrowing No (%)		118 (62.1%)	70 (36.8%)	2 (1.1%)	1.337	0.513
Erosion No (%)		6 (51%)	5 (49%)	0	1.53	0.821
Osteophytes No (%)		42 (53.8%)	34 (43.6%)	2 (2.6%)	6.875	0.032
Osteopenia No (%)		110 (60.4%)	70 (38.5%)	2 (1.1%)	5.706	0.058

Table 5: Association between DAA duration and patients 'complaints

	Duration of DAA treatment (weeks)		Pearson Chi-Square	Sign.
	12 weeks	24 weeks		
				p*
Headache No (%)	58 (34.9%)	18 (52.9%)	3.881	0.039
Fatigue No (%)	6 (3.6%)	2 (5.9%)	0.378	0.539
Bone ache No (%)	74 (44.6%)	16 (47.1%)	0.07	0.791
Shoulder pain No (%)	24 (14.5%)	4 (11.8%)	0.17	0.68
Knee pain No (%)	68 (41%)	16 (47.1%)	0.43	0.512
Back pain No (%)	46 (27.7%)	4 (11.8%)	3.827	0.05
Joint examination of affected joint				
Joint swelling No (%)	4 (2.4%)	0	0.836	0.361
Joint erythema No (%)	8 (4.8%)	0	1.707	0.191
Joint tenderness No (%)	164 (98.8%)	34 (100%)	0.414	0.52
Limited-joint mobility No (%)	84 (50.6%)	20(62.5%)	1.523	0.217

Table 6: association of age group of patients with clinical and radiological assessment of joints (n=200).

	Age groups/years			Pearson Chi-Square	Sign.P*
	Less-than 35yrs	35-55 yrs	More than 55 yrs		
Joint-swelling No (%)	0	2 (1.8%)	2 (3%)	0.866	0.649
Joint erythema No (%)	0	6 (5.5%)	2 (3%)	1.768	0.413
Joint tenderness No (%)	22 (91.7%)	110 (100%)	66 (100%)	14.815	0.001
Limited-joint mobility No (%)	8 (33.3%)	54 (49.1%)	42 (65.6%)	8.47	0.014
Radiological assessment of affected joints					
Joint narrowing No (%)	20 (83.3%)	106(96.4%)	64 (97%)	7.847	0.02
Erosion No (%)	0	0	11 (16.7%)	23.633	0
Osteophytes No (%)	4 (16.7%)	32 (29.1%)	42 (63.6%)	26.41	0
Osteopenia No (%)	22 (91.7%)	98 (89.1%)	62 (93.9%)	1.199	0.549

Table 7: association between gender of HCV patients with their complaint.

	Gender		Pearson Chi-Square	Sign. P*
	Male	Female		
Headache No (%)	30 (41.7%)	46 (35.9%)	0.642	0.423
Fatigue No (%)	6 (8.3%)	2 (1.6%)	5.501	0.019
Bone ache No (%)	36 (50%)	54 (42.2%)	1.136	0.286
Shoulder pain No (%)	8 (11.1%)	20 (15.6%)	0.78	0.377
Knee pain No (%)	24 (33.3%)	60 (46.9%)	3.469	0.063
Back pain No (%)	14 (19.4%)	36 (28.1%)	1.852	0.174

Limited joint mobility was common in age group >55 years (65.6%) followed by age group 35-55 years (49.1%) then age group <35 years (33.3%) and it was statistically significant $p^* = .014$. While joint swelling and erythema shows less than 5% in different age groups and it were statistically insignificant.

Radiological finding of affected joints showed that joint narrowing was more common in age group (>55) years old in (97%) patients followed by age group (35-55) years old in (96.4%) patients then age group (<35) years old in (83.35%) patients and it was statistically significant $P^* = 0.020$. Joint erosion was predominant in age group (>55) years old in (16.7%) patients and it was statistically significant $P^* = 0.00$. Osteophytes was common in age group (>55) years old in (63.6%) patients followed by age group (35-55) years old in (29.1%) patients then age group (<35) years old in (16.7%) patients and it was statistically significant $P^* = 0.00$. Osteopenia was common in age group (>55) years old in (93.9%) patients followed by age group (<35) years old in (91.7%) patients then age group (35-55) in (89.1%) patients and it was statistically significant $P^* = 0.549$.

Table (7) show that Fatigue (8.3%) was common in male than female (1.6%) and it was statistically significant $p^* = 0.019$. Headache (41.7%), bone pain (50%) were common in male than female (35.9%), (42.2%) respectively but it was statistically insignificant. Shoulder pain (15.6%), knee pain (46.9%), back pain (28.1%) were common in female than male (11.1%), (33.3%), (19.4%) respectively but it was statistically insignificant.

Discussion

Hepatitis C virus (HCV) infection is a worldwide disease affecting approximately 200 million people and considered a major cause of morbidity and mortality [2]. Hepatitis C virus affects the liver primarily; however, chronic HCV infection can cause several extrahepatic manifestations that can affect many systems, including skin, musculoskeletal, renal, cardiovascular, and nervous systems [3]. Extrahepatic manifestations develop in up to 74% of patients with chronic HCV infection during the disease course [4]. Musculoskeletal and rheumatologic extrahepatic manifestations associated with HCV infections are numerous. The actual prevalence of HCV-associated arthritis varies with a different population, it ranges from 4 to 12% of HCV-infected patients [5]. The previous standard therapy of HCV was the combination of pegylated interferon and ribavirin, but this was associated with either worsening of preexisting autoimmune disorders or even developing a new one besides the poor virologic response in some cases [6, 7]. The treatment of chronic HCV has been revolutionized with the introduction of the oral direct-acting antiviral (DAA) drugs, which specifically target virus-specific proteins. Sofosbuvir (SOF) and daclatasvir (DCV) are new generation DAA, which have proved high efficacy in treating HCV genotype 4 (the

commonest genotype in Egypt), especially when used in combination. The combination of SOF–DCV with or without ribavirin (RBV) has been entirely used for all patients in a national program adopted and completely funded by the Egyptian National Committee for Control of Viral Hepatitis (NCCVH) since 2016 [8]. Of note, since the introduction of new direct-acting antiviral agents (DAAs) and its funding by the Egyptian government, lead to HCV eradication and complete virologic response. There are few studies that have investigated the efficacy and safety of these drugs on HCV-related extra-hepatic manifestations [9]. Thus, the aim of the current study was to detect musculoskeletal manifestation in HCV patients receiving direct antiviral therapy in depth. This was a prospective randomized study conducted on a total of 200 Egyptian HCV patients complaining from musculoskeletal manifestation after receiving direct antiviral therapy (DAAs) attending Rheumatology & Immunology Unit and hepatology unit in internal medicine department in Mansoura university Hospital over a period of one year. All HCV patients (200) were diagnosed with Polymerase Chain Reaction (PCR) received direct antiviral drugs (DAAs), most of them 63% treated with Sofosbuvir+ Daclatasvir, 36% patients treated with Sofosbuvir+Daclatasvir+Ribavirin and only 1% received Sofosbuvir+Simeprevir. Duration of treatment was 12 weeks in 83% (166) patients and 24 weeks in 17% (34) patients with complete virologic response was achieved in 99% (198) patients as in Table 2. Of studied HCV patients, there was female predominance 65%, this result agreed with [10] who reported that female predominance in HCV patients with musculoskeletal manifestation, the most affected group was 35-55 years old in (55%) patients then age group more than 55 years in 33% patients old, fortunately 88% of them were non-smokers and these results matched with Fekry and his colleagues in their study on chronic HCV patients concluded that the mean age was 48.98 ± 12.08 years. 102 (80.32%) were non-smokers [11]. Majority of studied HCV patients 96% were married, 55% were unemployed these finding matched with [12] Table 1. [13] displayed that; the most recorded musculoskeletal adverse events associated with HCV treatment were Fatigue, headache, fever and worsening of ascites especially with (SOF + RBV, SOF + RBV + PEG-IFN alfa-2a), while the current study demonstrated that Most of the patients complained from bone pain 45% (90), knee pain 84 (42%), back pain 25% (50), shoulder pain 14% (28) while headache and fatigue are less common complaint among studied patient was mean complaint in 38%, 4% respectively figure (1), the discrepancy was due different sample size, protocol and duration of management of HCV. In the context of joint distribution, the present research demonstrated that; more than half 55% (110) of studied HCV patients had the knee as the most frequent affected joint, this was in contrast with [14] who reported (97,3%) of patients presented with knee joint, this contrast was due to different sample size and assessment it

was sonographic assessment of knee joint which leak in our study, While the least affected joint was the wrist 6% (12), the shoulder joint affection was 8% (16) of the patients and more than 30% of patients had more than one joint involvement. The course of arthralgia of studied group was unfortunately progressive in 85% (166) of the patients with 15% of them had regressive course as figure (2). Radiological assessment of affected joints; demonstrated that majority of patients 75% had osteopenia in more than one site (knee, hip, shoulder, foot) this result was matched with [15] concluded that more than of studied group had osteopenia. Joint narrowing in more one site (hip, knee, wrist, shoulder) was detected in more than fifty 55% of studied patients and joint erosion in 4% in the foot and 1% in more than one site, however, previous literature reported that hand joint narrowing and erosion was evident in 4% their studied patients [16], the contrast was the previous work assessed only the hand joint figure (3). It is peculiar to our work to study the ocular manifestation in chronic HCV with DAAS therapy, it was observed that Sicca syndrome 33%, conjunctivitis in 20% of them and only 2% of them required fundus examination while 8% of them treated conservative treatment and 5% required interventions. To date, there are no pathognomonic manifestations of HCV infection in the eye, though some ocular syndromes have been reported in case series and reports table 3. In correlation of DAAS therapy with patients complaints; it was noticed that fatigue was statistically significant associated with HCV patients treated with triple therapy Sofosbuvir/Daclatasvir+ ribavirin rather than those received Sofosbuvir/Daclatasvir, and it was in agreement with [17] who reported that fatigue was reported in HCV patients treated with triple therapy than dual one. While headache, arthralgia was evident 57.9%, 63% respectively in patients treated with dual therapy than patients treated with triple therapy 42.1%, 36% respectively. The previous literature reported that arthralgia was the most frequent in musculoskeletal manifestations (90%) among cases with HCV on DAAs therapy [18-21].

As regard clinical finding of joint examination, joint swelling, limited joint mobility was statistically significant in patients treated with dual therapy 100%, 52% respectively than treated with triple therapy, this is contradictory to the study carried by [22] who found that limited joint mobility and joint stiffness was more in patients treated with Sofosbuvir/Daclatasvir plus Ribavirin than patients treated with Sofosbuvir/Daclatasvir, The difference may be due to small sample size table (4). it was noticed that HCV patients treated with DAAS therapy for 24 weeks duration complained of headache, fatigue (52.9%) , (5.9%) respectively than those treated for 12 weeks (34.9%) , (3.6%) respectively and this was in agreement with [23] who stated that headache , fatigue were common in patients treated for 24 weeks than those treated for 12 weeks, while back pain was statistically significant in patients treated for 12 weeks duration (27.7%)

than those for 24 weeks (11.8%), previous research concluded that arthralgia and back pain were common DAAS therapy adverse effect for 12 weeks [24] Table (5). Correlation of age group with clinical joint assessment; it was observed that tenderness was the comments presentation in second and third tertials (100%) and 91.7% in first tertials this matched with [25] concluded that (65.8%) had articular pain and tenderness more in age group range in (34-78years), While joint narrowing, erosion and joint osteophytes were statistically significant in third tertials than first and second tertials, The previous paper stated that the mean age (41.39± 10.19) was associated with joint erosion, narrowing [10], this difference with different sample size. it was observed that the osteopenia was common in different age group; (93.9%) third tertials, (91.7%) first tertials and (89.1%) second tertials this matched with [15] who stated that chronic HCV patients had lower bone mineral density than healthy controls regardless line of treatment Table (6). It was observed that headache (41.7%) , fatigue (8.3%) were common statistically significant in males than females (35.9%), (1.6%) respectively and this was in agreement with [26] stated that male gender was risk factor for associated with side effects fatigue and headache(37%).

Limitation of study

Single center experience, to some extant small sample size, lack radiological assessment by musculoskeletal ultrasound.

Conclusion

Although, The efficacy of direct antiviral drugs (DAAs) to improve hepatic and extra-hepatic manifestations of hepatitis C viral infected patients, they have a burden on musculoskeletal system; bone pain (back, shoulder) and arthralgia (Wrist, knee, shoulder) were common with sofosbuvir and daclatasvir especially for 12 week duration and the most affected age group (more than 55year) with radiological evident in them.

Recommendation

- Dual therapy (Sofosbuvir Daclatasvir) carry high burden on musculoskeletal disorder than other lines.
- Frequent screening of musculoskeletal disorder in HCV patient treated with DAAs therapy.
- Ophthalmic examination is highly recommended in HCV patient treated with DAAs therapy.
- Radiological evolution (Plain X-ray, Musculoskeletal Ultrasound (MSUS)) can pick up

Ethical consideration

- Study protocol will be submitted for approval by Mansoura Medical Ethics Research committee (MMERC) of faculty of Medicine.

- Informed written consent was obtained.
- Confidentially and personal privacy will be respected in all levels of the study.
- Collected data will not be used for any other purposes.

Declarations

DOI (Declaration of conflict of interest)

No conflict of Interest to disclose

Competing interests

Not applicable

Funding

No external funds.

Consent to participate

Ethical approval from the patient was taken to share her data. Informed written consent to participate in the study was obtained from participants.

Confidentially and personal privacy was respected in all levels of the study.

Written Consent for publication

Informed written consent was taken from all patients to purplish these data and sharing photo.

Availability of data and materials

All data are confidential.

Code availability

All data available through main author

Authors' contributions

Marwa A. Besar; wrote full paper, result and discussion, build reference.

Doaa A. Anter, collecting data, build table, figure.

Adel I. Abd El Salam, Asmaa F. Enin, revise the paper.

Reference

1. WHO. Hepatitis C: fact sheet (2018).
2. Thomas DL. Global control of hepatitis C: where challenge meets opportunity. *Nature medicine* 19 (2013): 850-858.
3. Polo ML, Laufer N. Extrahepatic manifestations of HCV: the role of direct acting antivirals. *Expert review of anti-infective therapy* 15 (2017): 737-746.
4. Galossi A, Guarisco R, Bellis L, et al. Extrahepatic manifestations of chronic HCV infection. *Journal of Gastrointestinal and Liver Diseases* 16 (2007): 65.
5. Cacoub P, Comarmond C. New insights into HCV-related rheumatologic disorders: A review. *Journal of Advanced Research* 8 (2017): 89-97.
6. Boonyapisit K, Katirji B. Severe exacerbation of hepatitis C-associated vasculitic neuropathy following treatment with interferon alpha: a case report and literature review. *Muscle & nerve* 25 (2002): 909-913.
7. Saadoun D, Thibault V, Ahmed SNS, et al. Sofosbuvir plus ribavirin for hepatitis C virus-associated cryoglobulinaemia vasculitis: VASCUVALDIC study. *Annals of the rheumatic diseases* 75 (2016): 1777-1782.
8. Gomaa A, Allam N, Elsharkway A, et al. Hepatitis C infection in Egypt: prevalence, impact and management strategies. *Hepatic medicine: evidence and research* 9 (2017): 17.
9. Alian SM, Wahba MO, Gomaa AF, et al. The efficacy and safety of direct-acting antiviral drugs in the management of hepatitis C virus-related arthritis. *Egyptian Rheumatology and Rehabilitation* 47 (2020): 1-8.
10. Rasheed U, Nisar A, Aziz W, et al. Rheumatological manifestations of HCV patients at tertiary care hospital. *ins.Med.academia.edu*.2013. 9 (2013): 57-60.
11. Fekry M, Hashish M, Selim H, et al. Evaluation Of Direct Acting Antiviral Agents In The Treatment Of Patients With Chronic Hepatitis C Infection In Alexandria *JMRI* 39 (2018): 33-40
12. Gamaleldin and his colleagues, et al. Towards hepatitis C virus elimination: Egyptian experience, achievements and limitations, *World J Gastroenterol* 24 (2018):4330-4340.
13. Sarwar S, Khan AA. Sofosbuvir based therapy in Hepatitis C patients with and without cirrhosis: Is there difference? *Pakistan journal of medical sciences* 33 (2017): 37.
14. Iagnocco A, Giulio C, Antonio M, et al. Joint sonography in asymptomatic patients with HCV correlated hepatitis, *Clin Exp Rheumatol* 22 (2004): 43-48.
15. Martinez J, Lens S, Baiges A, et al. Clinical outcome and hemodynamic changes following HCV eradication with oral antiviral therapy in patients with clinically significant portal hypertension, *J Hepatol* 73 (2020): 1415-1424.
16. Bassiony H, El Dahan M, Zaky K, et al. Significance of Articular Hand Manifestations in Chronic HCV Patients, *Journal of Gastroenterology and Hepatology Research* 3 (2014): 11.
17. Moneim A, Aboud A, Gabaar M, et al. Efficacy and safety of sofosbuvir plus daclatasvir with or without ribavirin: large real-life results of patients with chronic hepatitis C genotype 4, *Hepatology International* (2018).

18. El Garf A, El Zorkany B, Gheith R, et al. Prevalence and clinical presentations of hepatitis C virus among patients admitted to the rheumatology ward. *Rheumatology international* 32 (2012): 2691-2695.
19. Cheng Z, Zhou B, Shi X, et al. Extrahepatic manifestations of chronic hepatitis C virus infection: 297 cases from a tertiary medical center in Beijing, China. *Chinese Medical Journal* 127 (2014): 1206-1210.
20. Elnoemany K, H El-Nadry M, F Mohamed S, et al. Impact Of Treatment With Direct Acting Antiviral Agents (Daas) On Mixed Cryoglobulinemia Of HCV Egyptian Patients. *Al-Azhar Medical Journal* 50 (2021): 719-732.
21. Mohammed RHA, ElMakhzangy HI, Gamal A, et al. Prevalence of rheumatologic manifestations of chronic hepatitis C virus infection among Egyptians. *Clinical rheumatology* 29 (2010): 1373-1380.
22. Gaber M, Sallam A, et al. Dermatological adverse effects of new era of direct-acting antivirals in hepatitis C virus treatment. *MMJ* 32 (2019): 1521-1527.
23. Shahin A, Zayed H, Said M, et al. Efficacy and safety of sofosbuvir-based, interferon-free therapy. *Zeitschrift für Rheumatologie*, 77 (2018): 621-628.
24. Bahatia H, Singh H, Grewal N, et al. Sofosbuvir: A novel treatment option for chronic hepatitis C infection, *J Pharmacol Pharmacother* 5 (2014): 278-284.
25. Nissen M, Fontanges E, Zoulim A, et al. Rheumatological manifestations of hepatitis C: incidence in a rheumatology and non-rheumatology setting and the effect of methotrexate and interferon. *Rheumatology* 44 (2005): 1016-1020.
26. Attia A, Ahmed H, Gadelkarim M, et al. Safety and efficacy of sofosbuvir plus velpatasvir with or without ribavirin for chronic hepatitis C virus infection: A systematic review and meta-analysis, *Journal of infection and public Health* 11 (2018): 156-164.