

Case Report

Pleomorphic Adenoma of the Cheek: Case Report and Literature Review

Andrea Avagnina¹, Luigi Schiraldi¹, Mariana Dalaqua², Stéphane Yerly³, Miranda Morrison¹, Bassel Hallak^{1*}, Salim Bouayed¹

¹Department of Otorhinolaryngology, Head and Neck Surgery, Hospital of Sion, Sion, Switzerland

²Department of Diagnostic imaging and Interventional Radiology, Hospital of Sion, Sion, Switzerland

³Department of Histocitology, Hospital of Sion, Sion, Switzerland

***Corresponding Author:** Dr. Bassel Hallak, Department of Otorhinolaryngology, Head and Neck Surgery, Hospital of Sion, Sion, Switzerland, E-mail: bassel.hallak@hopitalvs.ch

Received: 31 July 2020; **Accepted:** 11 August 2020; **Published:** 14 September 2020

Abstract

A 56-year-old man, with good general health, was addressed by his own physician to our ENT and cervico-facial surgery department with a chief complaint of a mass in the right cheek. The mass has been progressively growing over the last 15 years, and has become increasingly troublesome in the last 3 months. MRI imaging suggested a vascular malformation. Patient underwent an “en-bloc” surgical excision of the mass, which revealed a pleomorphic adenoma. Pleomorphic adenomas are benign neoplasms composed of mesenchymal and epithelial components. They most frequently occur in the major salivary glands. Ectopic localisations are very rare. Here we report a case of an ectopic pleomorphic adenoma in the subcutaneous layer of the cheek and a literature review.

Keywords: Pleomorphic adenoma; Adenoma; Cheek; Ectopic adenoma

1. Introduction

In general, salivary gland tumors account for 3% of head and neck neoplasms [1]. In addition, 9 to 23% of salivary gland tumors occur in minor glands. Pleomorphic adenoma (PA) is the most common tumor of the salivary gland, and principally it presents two components, epithelial and mesenchymal components [2]. It is the most common benign neoplasm which is reported in major salivary glands. At times they can also develop in minor salivary glands

of the palate [1]. We report a rare case of an ectopic pleomorphic adenoma of the right cheek which was found in the submucosal plane combined with a literature review on the subject.

2 Case Report

A 56-year-old healthy male was addressed to our ENT and cervicofacial department by his own physician following the progressive swelling of his right cheek since 15 years, a swelling that started to be increasingly troublesome in the last 3 months. There was no notion of systemic fever, localized heat or any discharge from the mass. In the patient's history, there was no history of similar lesions or of usual ENT risk factors. On clinical examination, we found a right jugal swelling and during bimanual palpation we found a mobile, roundish, painless and well circumscribed mass of the right cheek thickness. The size was 3 cm of diameter. The rest of the clinical examination was normal.

The patient presented for the first time for above complaint in our hospital. At first we suspected a benign lesion such as epidermal cyst, a vascular or a lymphatic malformation. To complete the clinical investigation we performed an MRI of the head. The images were assessed by an experienced radiologist in the ENT sphere and they evoked as primary hypothesis a benign vasculaire malformation (hemangioma) (Figure 1, Figure 2, Figure 3).

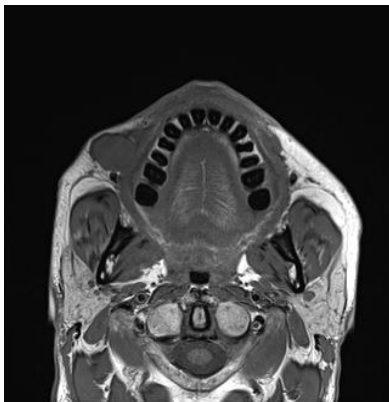

Figure 1: MRI- T1.

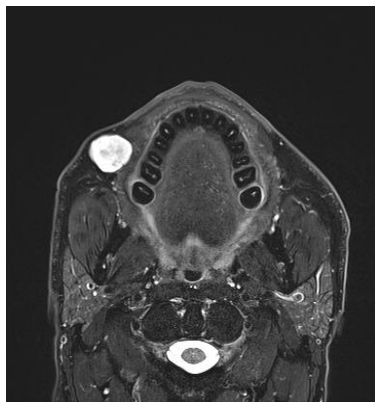


Figure 2: MRI-T2 gad.

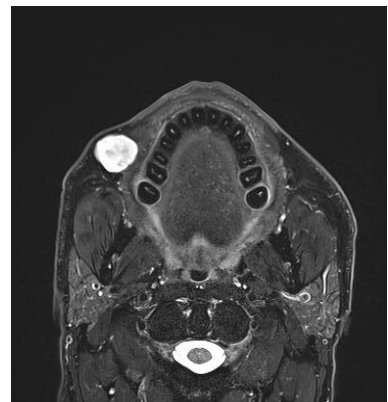


Figure 3: MRI-T2 Fat Sat.

The patient underwent surgery under general anesthesia. The incision line was designed on the jugal mucosa, following a vertical line close to the lesion and at least 2 cm away from the labial commissure to avoid damaging the facial artery. The incision was mucosal in order to avoid postoperative scarring on the face. A mass was revealed in the submucosal layer. It was well defined from around normal soft tissues. Complete excision was successfully done and the surgical wound was closed with primary repair, carried out with an absorbable thread. Excised mass was 3 × 2 × 1 cm, firm, multilobulated and of rubbery consistency (Figure 4, Figure 5).

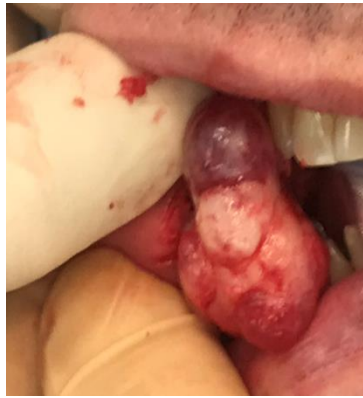

Figure 4: Mass exposure.

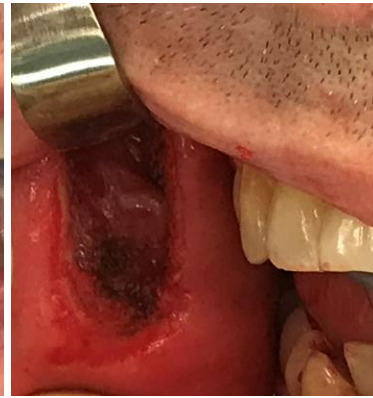

Figure 5: Total resection.

Histopathological examination revealed a pleomorphic adenoma which presents a roughly polylobulated, biphasic, epithelial/myoepithelial and stromal architecture. The stromal component is abundant and it shows a chondromyxoid aspect in appearance. (Figure 6, Figure 7).

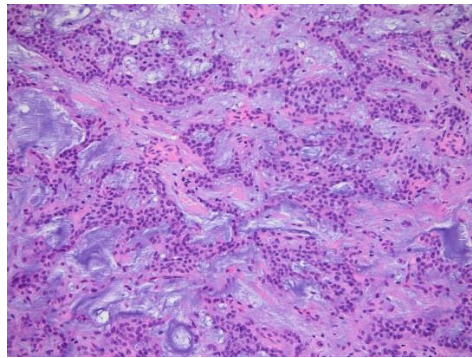


Figure 6: Histopathological examination, cross-sectional inspection of a mass (H&E, ×100).

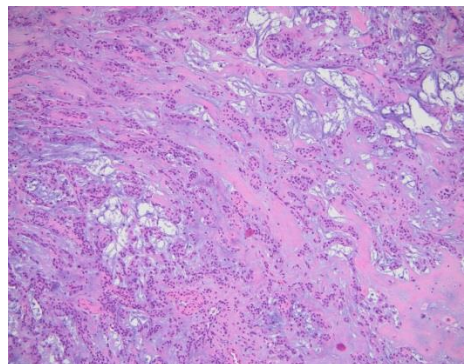


Figure 7: Pleomorphic adenoma which contains epithelial cells and myoepithelial cells with duct-like gland components (H&E, ×200).

3. Materials and Methods

Until March 2020, a systematic search of the literature was performed interrogating PubMed search engine. The following research algorithm was used pleomorphic adenoma cheek. A prefilled excel database was used to enter the records according to a defined exclusion criteria algorithm. Exclusion criteria applied hierarchically were: (I) not concerning a pleomorphic adenoma; (II) not concerning the cheek; (III) not in English; (IV) review articles; (V) no abstract available; (VI) non-extractable data; (VII) not human. Abstracts were manually screened by AA and LS separately, and subsequently matched for accuracy. Pertinent full-text articles were retrieved and analyzed, and data were extracted on the database. The flow chart of article selection is described following the Preferred Reporting Items for Systematic Reviews and Meta-Analyses (PRISMA) statement [3].

4. Results

The initial database literature search yielded 104 records, including duplicates and non-pertinent articles. After manual screening of the abstracts, 1 record were excluded due to being a duplicate in our search. The remaining 103 articles were further assessed for eligibility. At that stage, n=23 records were not concerning pleomorphic adenoma; n=10 had a different localisation, n=7 were not in English, n=7 were reviews or editorials were excluded from data analysis; n=24 didn't have an abstract available, n=5 had non-extractable data and n=1 was excluded because it was non human study concerning. A total of 26 [4-28] articles were identified and were included for data extraction. After exclusion, we found 79 patients including 18 females, 11 men and 50 were not available. The mean age was $39,04 \pm 18,3$ years old years old. The principal symptom was the cheek swelling which was present in 73 patients (92,4%). We found 56 patients (70,8%) who presented an accessory parotid gland (APG) - related tumor and 23 patients (29,2%) who revealed a minor salivary gland (MSG)-related tumor.

In the clinical assessment 5 CT scan, 6 MRI and 9 US were performed. No imaging were performed in 6 patients and for 56 patient this information was not available. Concerning the treatment, 77 (97,46%) patients received a surgical full resection, 1 (1,26%) patient was observed and about 1 patient the treatment was not available. The outcomes were satisfactory in 74 patients (93,67%) with total mass resection in 73 patients who had a surgical resection and 1 patient who was observed. Concerning 5 patients this data is not available. Only 2 patients (2,53%) presented a recurrence as a late complication.

5. Discussion

PA is the most common benign salivary gland neoplasm and it is also known as benign mixed tumor. It accounts for 60%-70% of all parotid neoplasias, 40%-60% of all submandibular neoplasias, and 40%-70% of minor salivary gland neoplasias [29, 30]. The most part of minor salivary glands are present in the oral cavity, spread between hard palate, buccal mucosa, and lips. Other sites are floor of the mouth, inferior surface of the tongue, palatoglossal folds, and tonsillar region. The prevalence is in women between fourth and sixth decade of age, male to female ratio varying from 1:1.4 to 1:1 [31]. The majority of intraoral mixed tumors have a mean size less than 3.0 cm [25]. A

retrospective Mexican study showed that in minor salivary gland tumors, 64.2% are benign neoplasms and only 35.8% were malignant [32]. Usually the patient presents a solitary and slow growing firm mass. Small tumors typically form smooth, mobile, firm mass but larger tumors tend to become a multi lobular lump and may attenuate the overlying skin or mucosa [30].

In our case, an ectopic pleomorphic adenoma appeared as a painless, mobile, roundish, and well circumscribed mass of the right cheek thickness, it showed a clinical presentation similar to benign soft tissue tumors. These findings of the case are in accordance with published studies [13, 33]. The differential diagnosis of PA cheek includes buccal abscess, dermoid cyst, sebaceous cyst, neurofibroma, lipoma, mucoepidermoid carcinoma and polymorphous low grade adenocarcinoma [34]. The size, extent of lesions and the bone involvement can be assessed by imaging like CT scan, MRI and ultrasonography which are useful tools during the pre operative phase [35]. Incisional biopsy of PA is contraindicated because can predispose to a recurrence. The preferred diagnostic modality is Fine needle aspiration cytology. PA ectopically exists even in the soft tissue of the neck, lymphonodes, tongue, mandible, hypophysis, mastoid bone, thyroid, parathyroid, subcutaneous layer of the nose, and skin of the external auditory canal [2].

According to Willis and colleagues, there are three hypotheses to explain this kind of heterotopias: abnormal differentiation of the local tissues (heteroplasia), abnormal persistence and development of vestigial structures and dislocation of portion of a deficient rudiment during mass movement and development [36]. It can happen due to metaplasia, neoplastic degeneration of ectopic salivary gland tissue or to the implantation after surgical excision of the salivary gland tumor [37]. The 5% of PA's cases can present a malignant transformation into carcinoma ex pleomorphic adenoma. Radiotherapy is not indicated as these carcinomas are usually radioresistant. An excellent prognosis was found (95%) after complete and wide excision [2]. PA can relapse in case of scattering, partial and incomplete excision or enucleation, any distant metastasis was discovered. In the literature a recurrence rate of 2-44% has been reported. The gold standard of treatment for PA is wide local surgical resection with good safety margins and follow-up for at least 3-4 years [30]. So an ectopic appearance can cause a diagnostic dilemma for surgeons and a pathological confirmation is crucial. PA is a benign tumor that mainly occurs in the salivary gland but as in this case, given the localization in the facial region an histopathological work-up is crucial in order to exclude other differential diagnosis [5]. Three histological subtypes were found, myxoid with an high rate of stroma (80%), cellular with myoepithelial cells predominating and mixed which is the classic form.

As already mentioned above, the gold standard treatment is complete surgical resection or eventually a “wait and see” strategy can be adopted. All literature is based on case reports and small size studies which present an high level of heterogeneity in the data reported.

Declaration

We hereby declare no conflict of interest. This article has no funding. All authors approved of the final manuscript as submitted. Patient's consent was obtained for this publication. This article was approved by the board institution committee of ethics. The availability of data and material was documented.

Contributors

AA contributed to reporting data acquisition and analysis of data. AA and SB wrote the first draft of the manuscript. MM contributed to data acquisition and proof reading. LS contributed to study design and data analysis. BH contributed to the interpretation and data analysis. SB contributed to data acquisition. MD contributed to assess MRI-images and to provide us selected photos. SY contributed to analyse the histology and to provide us selected photos. AA, SB, MM, LS, BH, contributed to the final writing and revising of the manuscript and checked for important intellectual content.

Acknowledgement

Not available for this case

References

1. Eveson JW, Cawson RA. Tumours of the minor. (oropharyngeal) salivary glands: a demographic study of 336 cases. *J Oral Pathol* 14 (1985): 500-509.
2. Ogle OE. Salivary Gland Diseases. *Dent Clin North Am* 64 (2020): 87-104.
3. Liberati A, et al. The PRISMA statement for reporting systematic reviews and meta-analyses of studies that evaluate healthcare interventions: explanation and elaboration. *BMJ* 339 (2009): b2700.
4. Periasamy S, Manoharan A, Garg H, et al. Pleomorphic Adenoma of the Cheek: A Case Report. *Cureus* 11 (2019): e5312.
5. Kim YH, Yoon HW, Kim J, et al. Ectopic pleomorphic adenoma on subcutaneous plane of the cheek. *Arch Craniofac Surg* 20 (2019): 55-57.
6. Ma H, et al. Pathology and management of masses in the accessory parotid gland region: 24-year experience at a single institution. *J Craniomaxillofac Surg* 46 (2018): 183-189.
7. Ananthaneni A, Undavalli SB. Juvenile cellular pleomorphic adenoma. *BMJ Case Rep* (2013).
8. Bablani D, et al. Pleomorphic adenoma of the cheek: a case report and review. *J Oral Maxillofac Surg* 67 (2009): 1539-1542.
9. Batrani M, Kaushal M, Sen AK, et al. Pleomorphic adenoma with squamous and appendageal metaplasia mimicking mucoepidermoid carcinoma on cytology. *Cytojournal* 6 (2008): 5.
10. Becelli R, Quarato D, Matarazzo G, et al. Surgical treatment of an extraparotid pleomorphic adenoma of minor salivary glands of the cheek. *J Craniofac Surg* 20 (2009): 1604-1606.

11. Bialek EJ, Jakubowski W, Karpinska G. Role of ultrasonography in diagnosis and differentiation of pleomorphic adenomas: work in progress. *Arch Otolaryngol Head Neck Surg* 129 (2003): 929-933.
12. Cohen MA. Pleomorphic adenoma of the cheek. *Int J Oral Maxillofac Surg* 15 (1986): 777-779.
13. Dalati T, Hussein MR. Juvenile pleomorphic adenoma of the cheek: a case report and review of literature. *Diagn Pathol* 4 (2009): 32.
14. Hamano T, et al. A case of accessory parotid gland tumor. *Tokai J Exp Clin Med* 29 (2004): 131-133.
15. Jayaram R, Patel D, Santhanam V. Benign pleomorphic adenoma of minor salivary gland showing perineural invasion: a rare entity. *Br J Oral Maxillofac Surg* 53 (2015): 81-82.
16. Jung YH, Hah JH, Sung MW, et al. Parotidotomy approach for a midcheek mass: a new surgical strategy. *Laryngoscope* 120 (2010): 495-499.
17. Lee BH. Unilateral agenesis of the parotid gland associated with a pleomorphic adenoma in the ipsilateral buccal space *Jpn J Radiol* 28 (2010): 224-226.
18. Lin DT, Coppit GL, Burkey BB, et al. Tumors of the accessory lobe of the parotid gland: a 10-year experience. *Laryngoscope* 114 (2004): 1652-1655.
19. Panigrahi RG, et al. Juvenile pleomorphic adenoma of masticator space: The first case report. *Contemp Clin Dent* 4 (2013): 527-530.
20. Ramachar SM, Huliappa HA. Accessory parotid gland tumors. *Ann Maxillofac Surg* 2 (2012): 90-93.
21. Sharma A, Deshmukh S, Shaikh A, et al. Pleomorphic adenoma of the minor salivary gland of the cheek. *Singapore Med J* 54 (2013): e183-184.
22. Sharma N. Pleomorphic adenoma of the buccal salivary gland: magnetic resonance imaging findings with differential diagnoses. *J Investig Clin Dent* 3 (2012): 228-231.
23. Tsegga TM, Britt JD, Ellwanger AR. Pleomorphic adenoma of the accessory parotid gland: case report and reappraisal of intraoral extracapsular dissection for management. *J Oral Maxillofac Surg* 73 (2015): 564-570.
24. Velpula N, Annam SR, Palapati SR, et al. Pleomorphic Adenoma of Cheek Masquerading as Fibrolipoma - Case Report with Review. *J Clin Diagn Res* 9 (2015): ZD13-15.
25. Verma P, Sachdeva SK, Verma KG, et al. Pleomorphic adenoma of cheek: a rare case report and review of literature. *Indian J Dent Res* 25 (2014): 122-124.
26. Vyas KC, Mathur SP. Pleomorphic salivary adenoma of cheek A case report *J Laryngol Otol* 98 421-423. (1984):
27. Yamamoto H, Fukumoto M, Yamaguchi F, et al. Pleomorphic adenoma of the buccal gland in a child *Int J Oral Maxillofac Surg* 15 (1986): 474-477.
28. Yasumoto M, Sunaba K, Shibuya H, et al. Recurrent pleomorphic adenoma of the head and neck *Neuroradiology* 41 (1999): 300-304.
29. Lopes MA, Kowalski LP, da Cunha Santos G, et al. A clinicopathologic study of 196 intraoral minor salivary gland tumours. *J Oral Pathol Med* 28 (1999): 264-267.

30. Moller K, Kohles N, Esser D. Surgery in Salivary Gland Diseases. *Laryngorhinootologie* 95 (2016): 709-732.
31. van Heerden WF, Raubenheimer EJ. Intraoral salivary gland neoplasms: a retrospective study of seventy cases in an African population. *Oral Surg Oral Med Oral Pathol* 71 (1991): 579-582.
32. Ledesma-Montes C, Garces-Ortiz M. Salivary gland tumours in a Mexican sample A retrospective study. *Med Oral* 7 (2002): 324-330.
33. Rao PK, Shetty SR, Hegde D. Ectopic pleomorphic adenoma. *N Am J Med Sci* 4 (2012): 190-192.
34. Jorge J, et al. Juvenile intraoral pleomorphic adenoma: report of five cases and review of the literature. *Int J Oral Maxillofac Surg* 31 (2002): 273-275.
35. Kaneda T, et al. Imaging tumors of the minor salivary glands. *Oral Surg Oral Med Oral Pathol* 78 (1994): 385-390.
36. Willis RA. Some unusual developmental heterotopias. *Br Med J* 3 (1968): 267-272.
37. Tsukuno M, Nakamura A, Takai S, et al. Subcutaneous pleomorphic adenomas in two different areas of the face *Scand. J Plast Reconstr Surg Hand Surg* 36 (2002): 109-111.

Citation: Andrea Avagnina, Luigi Schiraldi, Mariana Dalaqua, Stéphane Yerly, Miranda Morrison, Bassel Hallak, Salim Bouayed. Pleomorphic Adenoma of the Cheek: Case Report and Literature Review. *Archives of Clinical and Medical Case Reports* 4 (2020): 859-866.



This article is an open access article distributed under the terms and conditions of the [Creative Commons Attribution \(CC-BY\) license 4.0](https://creativecommons.org/licenses/by/4.0/)