

## Short Communication

# Severe Leukoplakia of the Vagina and Cervix Successfully Treated with Intravaginal Application of Topical Glucocorticoids

M Condic<sup>1\*</sup>, A Mustea<sup>1</sup>, DJ Ralser<sup>1</sup>, J Wenzel<sup>2</sup>, C Braegelmann<sup>2</sup>

<sup>1</sup>Department of Gynecology and Gynecological Oncology, University Hospital Bonn, Germany

<sup>2</sup>Clinic for Dermatology and Allergy, University Hospital Bonn, Germany

**\*Corresponding Author:** Mateja Condic, Department of Gynecology and Gynecological Oncology, University Hospital Bonn, Germany

**Received:** 18 January 2022; **Accepted:** 27 January 2022; **Published:** 10 February 2022

**Citation:** M Condic, A Mustea, DJ Ralser, J Wenzel, C Braegelmann. Severe Leukoplakia of the Vagina and Cervix Successfully Treated with Intravaginal Application of Topical Glucocorticoids. Archives of Clinical and Medical Case Reports 6 (2022): 63-65.

### Abstract

Leukoplakia of the vagina and cervix can hide (pre)malignant lesions or be caused by them, so biopsy and treatment is mandatory. Here we present a rare case of severe leukoplakia of the vagina and the cervix due to a chronic inflammatory reaction, which was successfully treated with intravaginal application of budesonide foam. In vulvar lesions, topical glucocorticoids are first line treatment, whereas intravaginal application is rare and pharmaceutical market lacks products for this indication. We describe a unique, well tolerated and successful

treatment of chronic inflammatory reactions of the vagina and cervix resulting in quick and complete remission.

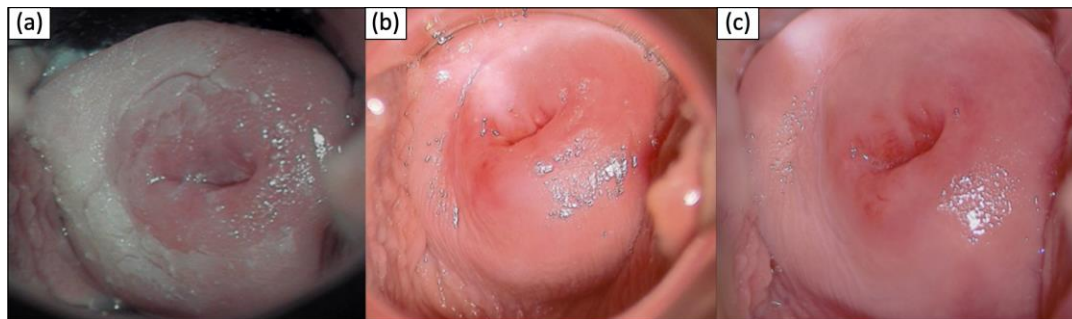
**Keywords:** Chronic inflammation; Cervical neoplasma; Hyperkeratosis; Leukoplakia

### 1. Synopsis of the Case

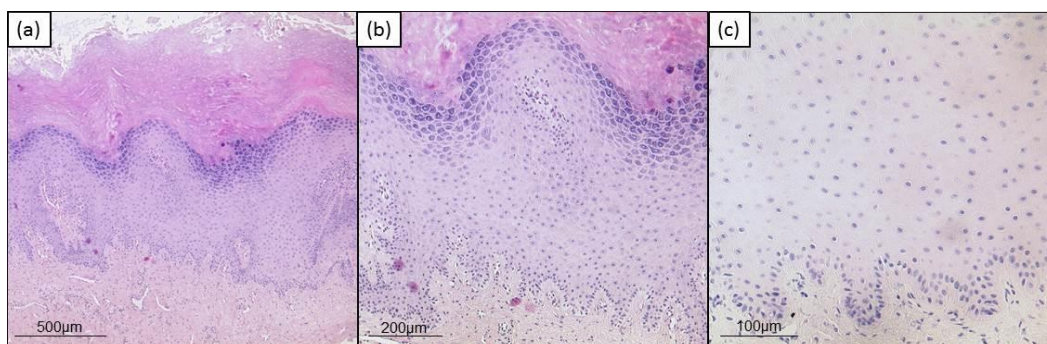
A 20-year old patient was referred to our gynecological department for colposcopy due to severe leukoplakia of the upper part of the vagina and cervix having persisted for more than one year. Two years before, she had been

diagnosed with low grade intraepithelial lesion of the cervix. Now, PAP smear cytology and HPV diagnostic were normal. She had received HPV vaccination as a teenager. She was an occasional smoker and did not suffer from chronic/autoimmune/dermatological diseases or allergies. For several years, she was taking a combined oral contraceptive pill. Several vaginal suppositories (antibiotics, lactobacillus, clotrimazol) had failed to achieve healing up. The colposcopy of the vagina and the cervix showed an extensive hyperkeratosis of the upper part of the vagina and the cervix (see Figure 1a). Due to tissue rigidity superficial loop electrical excision and laser therapy were necessary to obtain a sample after standard procedure for

biopsy taking had failed. Complete surgical treatment was impossible due to size of the leukoplakia. Histological examination revealed compact hyperkeratosis partially as parakeratosis above acanthotic epidermis featuring a pronounced stratum granulosum and mild spongiosis as well as perinuclear vacuolization of keratinocytes. Sparse inflammatory infiltrate with exocytosis of single lymphocytes was detected. No signs of malignancy were present. Findings were considered conformable with chronic inflammation or viral acanthoma. Immunohistochemistry and molecular pathology for HPV were negative (see Figure 2).



**Figure 1:** Timeline of clinical findings (colposcopy pictures). (a) initial finding (b) + 2 weeks treatment (c) + 3 months maintenance therapy



**Figure 2:** Histologic findings. (a) Hematoxylin and eosin staining, original magnification x50. (b) Hematoxylin and eosin staining, original magnification x100. (c) HPV staining (Anti Human Papilloma virus (HPV) Clone K1H8, Dako / Agilent (M3528), 1:50, pretreatment pH 6,0) original magnification x200.

In summary, as there were no signs for (pre)malignant lesions, HPV infection or any other acute disease, we decided to perform a local treatment with corticosteroids as the leading signs of histological analysis showed chronic inflammation. Besides discontinuation of oral contraceptives the patient hence applied budesonid rectal foam intravaginally once daily for 15 days. Subsequent colposcopy after two weeks showed complete remission (see Figure 1b). The patient did not have any discomfort. Budesonid foam was continued every three days for three months. Colposcopy did not show a relapse of the leukoplakia (see Figure 1c). Consequently, Budesonid application was discontinued which did not result in any relapse.

## 2. Discussion

Leukoplakia of the cervix appears as a white plaque before application of acetic acid. White coloration is caused by excessive keratin deposition and relative vascularity in epithelial cells. Leukoplakia can be idiopathic or induced by HPV infection. Also, cervical neoplasms and high grade lesions can induce keratin deposit and appear as leukoplakia. As they can hide premalignant lesions, leukoplakia patches in the transformation zone of the cervix should be biopsied [1]. In our case, we did not find a causal reason for the chronic inflammatory reaction underlying the severe leukoplakia. Sometimes, contraceptives can impact the vaginal microflora and genital tract immune cells enhancing the risk for infections [2]. Leukoplakia of the oral cavity is the most common potentially malignant lesion

and there appears to be some link between HPV infection and carcinomatous transformation [3]. Vulvar leukoplakia is most often associated with lichen sclerosis and is treated with topical corticosteroids due to risk of malignancy [4]. As cervical leukoplakia can hide (pre)malignant lesions or be caused by them, biopsy and treatment is essential. Compared to vulvar lesions, where topical glucocorticoids are first line treatment, intravaginal application is rare and pharmaceutical market lacks products for this indication.

## 3. Conclusion

Our case showed a unique, successful and well tolerated treatment with intravaginal application of budesonid foams, resulting in a quick and complete remission of an extensive leukoplakia of the vagina and cervix.

## References

1. Küppers VR. Revidierte kolposkopische und zytologische Nomenklaturen. Gynäkologie (2016).
2. Achilles SL, Hillier SL. The complexity of contraceptives: understanding their impact on genital immune cells and vaginal microbiota. AIDS 27 (2013): S5-15.
3. Feller L, Lemmer J. Cell transformation and the evolution of a field of precancerization as it relates to oral leukoplakia. Int J Dent 2011 (2011): 321750.
4. Yordanov A, Tantchev L, Kostov S, et al. Vulvar leukoplakia: therapeutic options. Prz Menopauzalny 19 (2020): 135-139.



This article is an open access article distributed under the terms and conditions of the [Creative Commons Attribution \(CC-BY\) license 4.0](https://creativecommons.org/licenses/by/4.0/)