



MULTIPLE HEADS OF DELTOID MUSCLE


Pavitra Alva and Dr. Shaheen Sajid Rizvi

Department of Anatomy, K. J. Somaiya Medical College, Somaiya, Ayurvihar, Eastern Express Highway, Sion, Mumbai-400 022

ABSTRACT: During routine dissection for 1st MBBS students on a 65 year donated embalmed male cadaver in the Department of Anatomy, K. J. Somaiya Medical College, we observed the multiple heads of the deltoid muscle in the left arm. The posterior fibers of the left deltoid muscle were enclosed in a distinct fascial sheet and the deltoid muscle was seen to arise from the middle 1/3 of the vertebral border of the scapula. However there was no variation in the blood supply and the nerve supply of the deltoid muscle. The photographs were taken for proper documentation. The existence of the multiple heads of the deltoid muscle should be kept in mind by surgeons operating on deltoid, posterior deltoid, or doing scapular flaps.

Key words: Deltoid Muscle, Multiple Heads, Variations, Vertebral Border of Scapula, Scapular Flaps, Surgeons.

*Corresponding autor: Dr. Shaheen Sajid Rizvi, Department of Anatomy, K. J. Somaiya Medical College, Somaiya, Ayurvihar, Eastern Express Highway, Sion, Mumbai-400 022; Email : rizvi.shaheen68@gmail.com

Copyright: ©2018 Dr. Shaheen Sajid Rizvi. This is an open-access article distributed under the terms of the Creative Commons Attribution License , which permits unrestricted use, distribution, and reproduction in any medium, provided the original author and source are credited

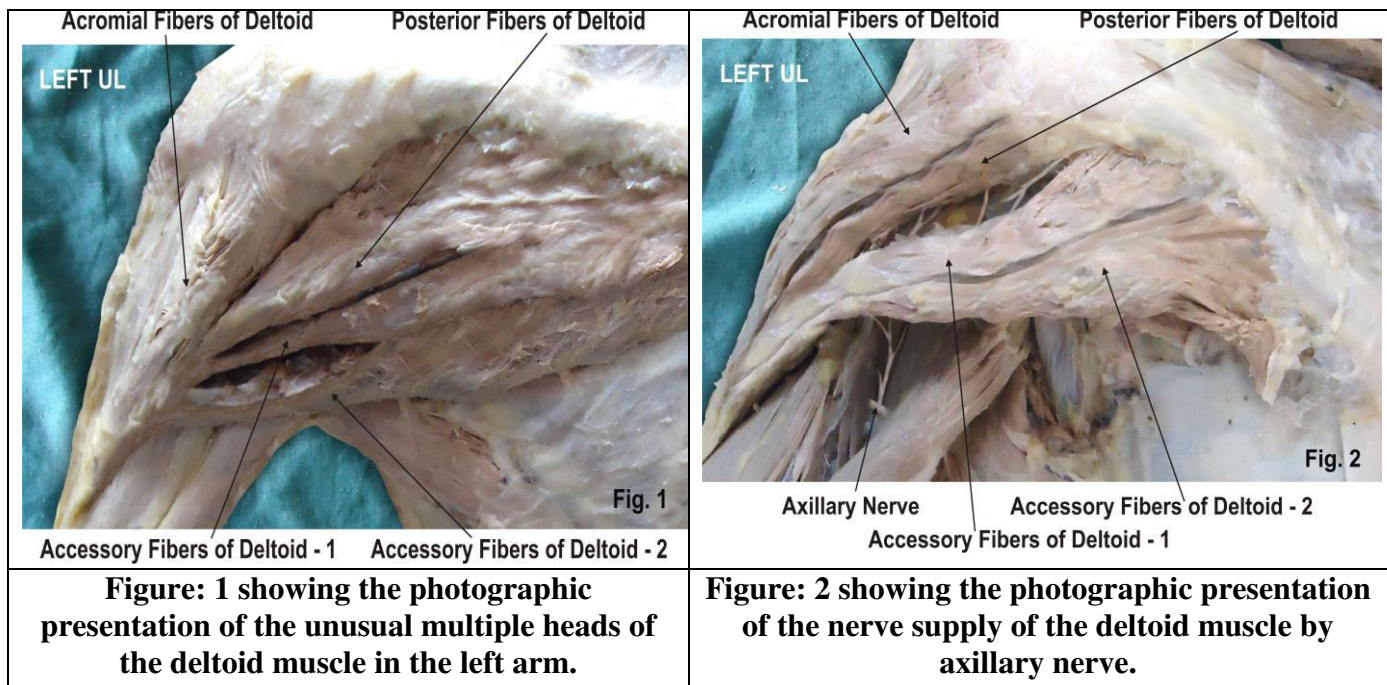
INTRODUCTION

The deltoid muscle which forms the rounded contour of the shoulder is made up of three distinct sets of fibers though electromyography it consists of at least seven groups that can be independently coordinated by the central nervous system. The anterior or clavicular fibers arise from the anterior border and upper surface of the lateral third of the clavicle. The anterior origin lies adjacent to the lateral fibers of the pectoralis major muscle as do the end tendons of both muscles. These muscle fibers are closely related and only a small chiasmatic space, through which the cephalic vein passes, prevents the two muscles from forming a continuous muscle mass. Lateral or acromial fibers arise from the superior surface of the acromion process. They are commonly called lateral deltoid. Posterior or spinal fibers arise from the lower lip of the posterior border of the spine of the scapula [1]. Fick divided these three groups of fibers into seven functional components; the anterior part has two components (I and II); the lateral one (III); and the posterior four (IV, V, VI, and VII) components. In standard anatomical position (with the upper limb hanging alongside the body), the central components (II, III, and IV) lie lateral to the axis of abduction and therefore contribute to abduction from the start of the movement while the other components (I, V, VI, and VII) then act as adductors. During abduction most of these latter components (except VI and VII which always act as adductors) are displaced laterally and progressively start to abduct [2]. From this extensive origin the fibers converge toward their insertion on the deltoid tuberosity on the middle of the lateral aspect of the shaft of the humerus; the middle fibers passing vertically, the anterior obliquely backward and laterally, and the posterior obliquely forward and laterally. The deltoid insertion is divided into two or three discernible areas corresponding to the muscle's three areas of origin. The insertion is an arch-like structure with strong anterior and posterior fascial connections flanking an intervening tissue bridge.

It additionally gives off extensions to the deep brachial fascia and is connected to the medial and lateral intermuscular septa [3]. The deltoid is innervated by the axillary nerve. The axillary nerve originates from the ventral rami of the C5 and C6 cervical nerves, via the superior trunk, posterior division of the superior trunk, and the posterior cord of the brachial plexus. The deltoid is supplied by the posterior circumflex humeral artery. When all its fibers contract simultaneously, the deltoid is the prime mover of arm abduction along the frontal plane. The arm must be medially rotated for the deltoid to have maximum effect. This makes the deltoid an antagonist muscle of the pectoralis major and latissimus dorsi during arm adduction. The anterior deltoid works in tandem with the subscapularis, pectorals and latissimus dorsi to internally rotate the humerus. The posterior fibers are strongly involved in transverse extension particularly as the latissimus dorsi is very weak in strict transverse extension. The posterior deltoid is also the primary shoulder hyper extensor, more so than the long head of the triceps which also assists in this function. The lateral fibers perform basic shoulder abduction when the shoulder is internally rotated, and perform shoulder transverse abduction when the shoulder is externally rotated. They are not utilized significantly during strict transverse extension (shoulder internally rotated) such as in rowing movements, which use the posterior fibers [4]. An important function of the deltoid in humans is preventing the dislocation of the humeral head when a person carries heavy loads. The function of abduction also means that it would help keep carried objects a safer distance away from the thighs to avoid hitting them, such as during a farmer's walk. By pulling the clavicle and scapulae up, it reduces compression and possibly impingement on the inferior borders so it doesn't press as much against the uppermost ribs. The deltoid is responsible for elevating the arm in the scapular plane and its contraction in doing this also elevates the humeral head. To stop this compressing against the under surface of the acromion the humeral head and injuring the supraspinatus tendon, there is a simultaneous contraction of some of the muscles of the rotator cuff: the infraspinatus and subscapularis primarily perform this role. In spite of this there may be still a 1–3 mm upward movement of the head of the humerus during the first 30° to 60° of arm elevation [5].

Case Report

During routine dissection for 1st MBBS students on a 65 year donated embalmed male cadaver in the Department of Anatomy, K. J. Somaiya Medical College, we observed the multiple heads of the deltoid muscle in the left arm. The posterior fibers of the left deltoid muscle were enclosed in a distinct fascial sheet and the deltoid muscle was seen to arise from the middle 1/3 of the vertebral border of the scapula. However there was no variation in the blood supply and the nerve supply of the deltoid muscle. The photographs were taken for proper documentation. The existence of the multiple heads of the deltoid muscle should be kept in mind by surgeons operating on deltoid, posterior deltoid, or doing scapular flaps.



DISCUSSION

Large variations and anomalies of Deltoid muscle are uncommon. More or less splitting is common. The continuation of the fibers of the deltoid muscle into the trapezius; fusion with the pectoralis major; and the presence of additional slips from the vertebral border of the scapula, infraspinous fascia, and the axillary border of scapula are the commonly reported variations of the deltoid muscle [6]. Bilateral separation of the posterior fibers with a fascia has been described in 1993 [7]. In the present case a very rare variation of the multiple heads of the deltoid muscle is reported because of its clinical and anatomical relevance. Such type of unilateral separations of the multiple heads of the posterior fibers of the deltoid muscle has not been found in literature. The deltoid muscle is derived from the dorsal muscle mass of the limb bud which is formed by somatic mesoderm during the fifth intrauterine week. The myogenic cells coalesce into two muscle masses during the fifth intrauterine week. One is the precursor of the flexor muscles the other is the precursor of the extensor muscles. These common muscle masses then split into anatomically recognizable precursors of the definitive muscles of the limb. The multiple heads of the deltoid may be developed because of incorrect splitting of the dorsal muscle mass [8,9].

Clinical anatomy

The axillary nerve is sometimes damaged during operations on the axilla, such as for breast cancer. It may also be injured by anterior dislocation of the head of the humerus. Clinically fasciocutaneous, musculocutaneous or muscular deltoid and posterior deltoid flaps are especially used in tetraplegia, reconstruction of extremity and rotator cuff tears. While elevating musculocutaneous or muscular deltoid and posterior deltoid flaps, the surgeon must be aware of the possibility of multiple heads of the deltoid muscle because it may cause confusion when dissecting the borders. Also an accessory deltoid may be confused with the teres major muscle because of its location and its distinct fascia and as a result of this the dissection of the pedicle can be much more difficult.

CONCLUSION

The axillary nerve is sometimes damaged during operations on the axilla, such as for breast cancer and be injured by anterior dislocation of the head of the humerus The existence of such variation of multiple heads of the deltoid muscle should be kept in mind by surgeons operating on deltoid, shoulder joint or doing scapular flaps.

ACKNOWLEDGEMENT

Authors are thankful to Dean Dr. Vinayak Sabnis Sir for his support and encouragement. Authors are also thankful to Mr. M. Murugan, Mrs. Pallavi Kadam, Mr. Shivaji Dalvi, Mr. Kishor Rangle, Mr. Shankush Adkhale, Mr. Sanjay Shinde, Mr. Kishor Beradiya and Mr. Panduj for their help. Authors also acknowledge the immense help received from the scholars whose articles are cited and included in references of this manuscript. The authors are also grateful to authors / editors / publishers of all those articles, journals and books from where the literature for this article has been reviewed and discussed.

Conflict of Interest

The authors declare that they have no conflict of interest.

Statement of Human and Animal Rights

All procedures performed in human participants were in accordance with the ethical standards of the institutional research committee and with the 1964 Helsinki declaration and its later amendments or comparable ethical standards. This article does not contain any studies with animals performed by any of the authors.

REFERENCES

- [1] The Anatomy of the Shoulder Muscles: "Deltoid Muscle". 2011. *Wheeless' Textbook of Orthopaedics*.
- [2] Standring S, editor. 2005. The anatomical basis of clinical practice. International 39th ed. Churchill Livingstone; Gray's Anatomy; p. 836.
- [3] Leijnse, J N A L; Han, S-H; Kwon, Y H 2008. "Morphology of deltoid origin and end tendons – a generic model". *J Anat* 213 (6): 733–742.

- [4] Brown JM, Wickham JB, McAndrew DJ, Huang XF. 2007. Muscles within muscles: Coordination of 19 muscle segments within three shoulder muscles during isometric motor tasks. *J Electromyogr Kinesiol.* 17(1):57-73.
- [5] Potau JM, Bardina X, Ciurana N, Camprubí D. Pastor JF, de Paz F. Barbosa M. 2009. Quantitative Analysis of the Deltoid and Rotator Cuff Muscles in Humans and Great Apes. *Int J Primatol* 30:697–708.
- [6] Sharadkumar. 2012. The axillary nerve giving motor branch to the long head of the triceps muscle – a case report. *IJAPBS Volume: 1: Issue-4:*
- [7] Kayikcioglu A, Celik HH, Yilmaz E. 1993. An anatomic variation of the deltoid muscle (case report) *Bull Assoc Anat (Nancy); 77:15–6.*
- [8] Larsen WJ. 2001. 3rd ed. *Human embryology*; Churchill Livingstone;. p. 324.
- [9] Carlson BM. 2004. *Human embryology and developmental biology.* 3rd ed. C.V. Mosby; p. 224.
- [10] Rispoli, Damian M.; Athwal, George S.; Sperling, John W.; Cofield, Robert H. 2009. "The anatomy of the deltoid insertion". *J Shoulder Elbow Surg* 18: 386–390.

International Journal of Plant, Animal and Environmental Sciences

